



ORIGINAL ARTICLE

Effect of age and sex in renal function by ultrasound and serum chemistry in two primate species (*Alouatta caraya* and *Sapajus apella*)

Gessiane Pereira da Silva¹  | Thyago Habner de Souza Pereira¹ | Aline Amaral Imbeloni² | Rafael do Santos de Andrade² | Ramiro das Neves Dias Neto³ | Leandro Nassar Coutinho¹  | Ana Paula Gering⁴ | Marina Sette Camara Benarrós⁴ | José Jones Pereira Junior⁵ | Frederico Ozanan Barros Monteiro¹ | Rafaela S. C. Takeshita⁶

¹Programa de Pós-graduação em Saúde e Produção Animal na Amazônia, Universidade Federal Rural da Amazônia (UFRA), Belém, Brazil

²Centro Nacional de Primatas (CENP), Instituto Evandro Chagas (IEC), Ananindeua, Brazil

³BioParque, Rio de Janeiro, Brazil

⁴Programa de Pós-Graduação em Sanidade Animal e Saúde Pública nos Trópicos (PPGSaspt), Universidade Federal do Tocantins (UFT), Araguaína, Brazil

⁵Programa de Pós-graduação em Saúde Animal na Amazônia, Universidade Federal do Pará, Castanhal, Brazil

⁶Department of Anthropology, Kent State University, Kent, Ohio, USA

Correspondence

Gessiane Pereira da Silva, Universidade Federal Rural da Amazônia (UFRA)/ Instituto da Saúde e Produção Animal (ISPA), Avenida Presidente Tancredo Neves, N° 2501, Bairro: Terra Firme Cep: 66.077-901, Belém, Pará, Brazil. Email: gessyane05@hotmail.com

Funding information

National Science Foundation, Grant/Award Number: 212357; Wenner-Gren Foundation, Grant/Award Number: 10088; Coordination for the Improvement of Higher Education Personnel, Grant/Award Number: 21/2018; National Council of Technological and Scientific Development, Grant/Award Number: 316750/2021-2, 400881/2019-5 and 305821/2017-2

Abstract

Background: Comparative studies of kidney morphophysiology in nonhuman primates can help us investigate interspecies differences in growth and aging patterns.

Methods: We tested the effect of age and sex in renal morphophysiology in 21 *Alouatta caraya* and 21 *Sapajus apella* (age range = 0.5–26 years) by ultrasound, red blood cell (RBC) count, and kidney function tests.

Results: *A. caraya* had greater growth rate and absolute renal volume than *S. apella*, but the latter showed a greater relative renal volume and RBC count. There was a negative relationship between RBC and age, a positive relationship between creatinine and body mass, and an apparent negative relationship between creatinine and age only in *S. apella*.

Conclusions: Our results indicate that *A. caraya* has a faster aging mechanism than *S. apella*, and the higher relative kidney volume in *S. apella* is suggestive of high metabolic demands in this species.

KEYWORDS

aging, nonhuman primates, renal morphophysiology, ultrasonography

1 | INTRODUCTION

Kidneys are important metabolic organs due to their function in excretion, filtration, water balance, blood pressure, and in the production of erythropoietin (EPO) to stimulate red blood cell (RBC) production.^{1–3} When the kidneys are damaged, their function may be compromised, which could result in anemia, high blood pressure, or even renal failure,^{2,4} which can be fatal. Assessment of renal function is therefore essential in clinical settings as a screening tool and for monitoring disease progression in primate husbandry.

While renal function tests commonly include urea and creatinine, early detection of renal alterations are useful in preventing aggravation of the clinical condition. One potential indicator of renal alteration in humans is low renal volume,^{5,6} which can indicate a reduction in the number of nephrons and predict risk of renal diseases.^{5,7} However, ultrasound data showed variations in renal biometric parameters with advancing age in humans and nonhuman primates (NHP), such as a progressive growth into adulthood, followed by size reduction in elder *Aotus azarae infulatus*⁸ and humans.⁶ To account for these differences, we must establish reference values for renal biometric parameters per age class for each species.

In addition to the clinical importance of monitoring renal function, comparative studies can help us understand species differences in aging mechanisms. The renal aging process is marked by the loss of nephrons and a reduction in the glomerular filtration rate, leading to a loss of functioning renal mass.⁹ In addition, macroscopic changes such as reduction in cortical volume, greater medullary volume, and the occurrence of cysts have been reported in elder humans.^{6,9} Furthermore, age can influence renal function tests in NHP,^{8,10,11} the responsiveness to EPO, and consequently, RBC count, which has been associated to increased rates of anemia in elderly patients.^{12,13} However, whether these age-related changes correlate with changes in renal morphology remains to be investigated.

Nonhuman primates are excellent comparative models for study the aging process due to their phylogenetic similarities with humans, but also due to their great diversity in life-history traits. For example, the genus *Alouatta* (howler monkeys) and *Sapajus* (capuchin monkeys) are platyrrhine primates from the families Atelidae and Cebidae, respectively. *A. caraya* weights about 5 kg for females and 7.8 kg for males,¹⁴ with a mean gestational period of 6 months, an inter-birth interval of 15.8 months,^{15,16} and a longevity of approximately 26 years in captivity.¹⁷ *S. apella* are relatively smaller, weighing approximately 3 kg for females and 4 kg for males,^{18,19} but have similar reproductive traits, with a mean gestational period of 5 and 20 months of interbirth interval.^{20–22} Despite the smaller body size and similar reproductive traits, *S. apella* has a longevity of up to 50 years in captivity,²³ which is almost double that of *A. caraya*. Considering this remarkable difference in longevity, the comparative study of age-related changes in kidney morphology and their effect in renal function tests in NHP can help us understand evolutionary mechanisms of senescence.²⁴

Previous studies have characterized kidney size in different age classes in NHP such as *Callithrix jacchus*,²⁵ *A. azarae infulatus*,⁸ *Saimiri collinsi*,²⁶ and *Macaca fascicularis*.²⁷ Although a few studies have described the renal ultrasonography in *Alouatta fusca*,²⁸ and *S. apella*,^{29,30} these studies were limited to adults. The goal of this study was to evaluate the kidney by ultrasound in infant, juvenile, and adults *A. caraya* and *S. apella* to (1) describe age-related changes in renal ultrasonographic appearance, (2) establish the renal biometric parameters per age group, (3) compare species differences in renal volume and kidney growth, and (4) to test potential correlations between renal volume and age, renal function tests (urea and creatinine) and RBC.

2 | METHODS

2.1 | Humane care guidelines

The experimental project followed the guidelines of the Brazilian Council for the Control of Animal Experimentation—Ministry of Science and Technology (CONCEA-MCT, Brazil), and was approved by the Ethics Committee for the Use of Animals (CEUA no. 43/2019 and 24/2021) of the Institute Evandro Chagas (IEC), Ananindeua, Pará, Brazil and by the Biodiversity Authorization and Information System of the Chico Mendes Institute of Biodiversity (Sisbio/ICMBio, protocol 38529-9).

2.2 | Subjects

The animals belonged to the breeding colony of the National Primate Center (Centro Nacional de Primatas—CENP, Ananindeua, Pará, Brazil, 1°38'26", 48°38'22"). We identified each animal using a three-letter code tattooed on the right thigh and a microchip placed in the interscapular area.

The subjects were 21 *A. caraya* (12 females and nine males), with a mean \pm SD body mass of 5.13 ± 3.4 kg (0.9–14.1 kg) and 21 *S. apella* (11 females and 10 males), with a mean \pm SD body mass of 2.12 ± 0.79 kg (0.9–3.95 kg). We classified the animals in three age groups, according to the literature available for each species. For *A. caraya*, there were three infants (<1 year; 6.6 ± 0.58 months), 10 juveniles (1.5–4 years; 2.6 ± 0.74), and eight adults (6–26 years, 12.5 ± 6), based on the classification proposed by Rímoli.³¹ For *S. apella*, there were four infants (<2 years; 11 ± 4.12 months), 10 juveniles (2–4 years; 2.7 ± 0.95), and seven adults (5–21 years, 16.85 ± 6), based on the classification proposed by Fragaszy et al.²³

All primate colonies at CENP are submitted to annual health screenings, which include physical examination, hemogram, and biochemical tests, in addition to deworming treatment. None of the animals used in this study had a history of infectious diseases as per their last health screening (2 months before data collection).

2.3 | Husbandry

All individuals lived in family groups of up to 10 individuals. They were kept in sheds and positioned in a north–south orientation to receive ≤ 12 h of natural light, in enclosures measuring $3.75 \text{ m} \times 2.2 \text{ m} \times 2.4 \text{ m}$ (*A. caraya*), and $3.85 \text{ m} \times 2.6 \text{ m} \times 2.5 \text{ m}$ (*S. apella*). The enclosures had external and internal water bottles and multiple bowls for food provisioning. The animals were fed according to CENP's standard management practices. Their diet contained different types of fruits and vegetables, eggs, and commercial primate food with 18% crude protein (Cebidae P18 Megazoo, portion Megazoo, Betim, Minas Gerais, Brazil). We also provided daily supplements of amino acids, vitamins, macro and micro minerals, and 0.5 g of Aminomix Pet® (Vetnil Ind. Veterinary Products Ltda.) per kg of body mass. Water was offered ad libitum.

2.4 | Capture and sample collection

Following an 8 h fasting period, the animals were contained physically with the aid of nets and chemically by intramuscular administration of a combination of ketamine hydrochloride (5 mg/kg), dexmedetomidine (0.01 mg/kg), and midazolam (0.2 mg/kg). With the animal contained, we collected between 0.5 and 3 ml of blood from the femoral vein with sterile syringes and needles (14–21 G, depending on the species and age of the animal). Blood samples were equally divided in two and transferred to two tubes: one containing ethylenediamine-tetraacetic acid (EDTA) for the hemogram procedure and one without anticoagulants for clinical chemistry (see below).

After blood collection, a trained veterinarian conducted a clinical evaluation in each animal by inspection, auscultation, palpation, and percussion.

2.5 | Ultrasound exams

To prepare the animals for the ultrasound exams, we shaved the hair in their abdominal region to avoid hair-product artifacts and applied an acoustic transmission gel (Carbogel, São Paulo, São Paulo, 04143-010, Brazil) to the shaven area to enhance ultrasonographic images. The exams were performed with an ultrasound system (Esaote® model Mylab Gamma), equipped with a linear and multifrequency electronic probe transducer of 4–13 MHz, in mode B. The animals were placed in three distinct positions (supine, right, or left lateral) to examine the entire abdominal region outlined by three limits: the last pair of ribs and the xiphoid cartilage (cranial limit), the transverse process of lumbar vertebrae (lateral limit), and the inguinal region (caudal limit).²⁹ First, to exclude the possible presence of other diseases that could affect laboratorial exams, we examined the liver and adrenal gland for potential alterations (e.g., cysts, gallstones, steatosis). In sequence, we evaluated the shape, echotexture, and size of both kidneys following the protocol previously reported in *A. azarae infulatus*⁸ and *S. collinsi*.²⁶ Renal length (L) and height (H) were measured using sagittal scans, and renal width

(W) was measured at the hilus using transverse scans (Figure 1). Renal volume was calculated (cm^3) by approximating the spheroidal geometric model from the 3 linear measurements ($L \times H \times W \times \pi/6$, where π is 3.1416) for each kidney. To determine the relative renal volume per individual, we calculated the mean renal volume from the left and right measurements, then divided the value obtained by the body mass. The growth rate was calculated per species for all biometric parameters (length, height, width, absolute volume). First, we calculated the mean values of each parameter for infant and adult classes. We then subtracted the infant means from the adult means and divided this value by the infant means. The results were expressed in percentage.

2.6 | Laboratory tests

Hemograms were performed with an MS4+ blood analyzer (Melet Schloesing GmbH Central & Eastern Europe company, Sudstadtzentrum 1, Top 8, 2346 Maria Enzersdorf-Suñstadt, Austria) to determine Red Blood Cell (RBC) count, Hemoglobin (Hb), Hematocrit (Hct), Mean Corpuscular Hemoglobin (MCH), Mean Corpuscular Volume (MCV), Mean Corpuscular Hemoglobin Concentration (MCHC), White Blood Cell (WBC) count, and platelets. The clinical chemistry tests were performed on Sistema Vitros DTSC II, DT60 and DTE2 (Johnson & Johnson Medical Argentina), to determine urea and creatinine. For statistical analyses, we used only urea, creatinine, and RBC. The other parameters were used to exclude any potential illness (infection, anemia) that could be associated with kidney alterations.

2.7 | Statistical analysis

All statistical tests were performed in R software (3.3.0). The means obtained from the right and left kidneys were compared by Student's *t* test. General Linear Models (GLM) were used to test the effects of age, sex, and species, on biometric and blood parameters. First, the possibility of multicollinearity was excluded by calculating the Variance Inflation Factor (VIF) with the “car” package. Since all factors had $VIF < 2$, none were considered problematic in the model. To assess the equality of variances of categorical fixed factors (sex and species), we used Levene's test.³² All values are expressed as the mean \pm standard deviation. Differences with a *P* value of $\leq .05$ or less were considered significant.

Five models were built to the following variables (response factors): absolute kidney volume, relative kidney volume, RBC, creatinine, and urea. For the biometric parameters, we initially included age, body mass, species, sex, and interactions as fixed factors. As for blood parameters, age, body mass, species, sex, and relative renal volume were initially included as fixed factors. Following Burnham and Anderson,³³ we sequentially removed fixed factors to select the model with the lowest Akaike Information Criterion with correction for small sample sizes (AICc). If the AICc difference between two models (ΔAICc) was less than 2, both models were discussed.

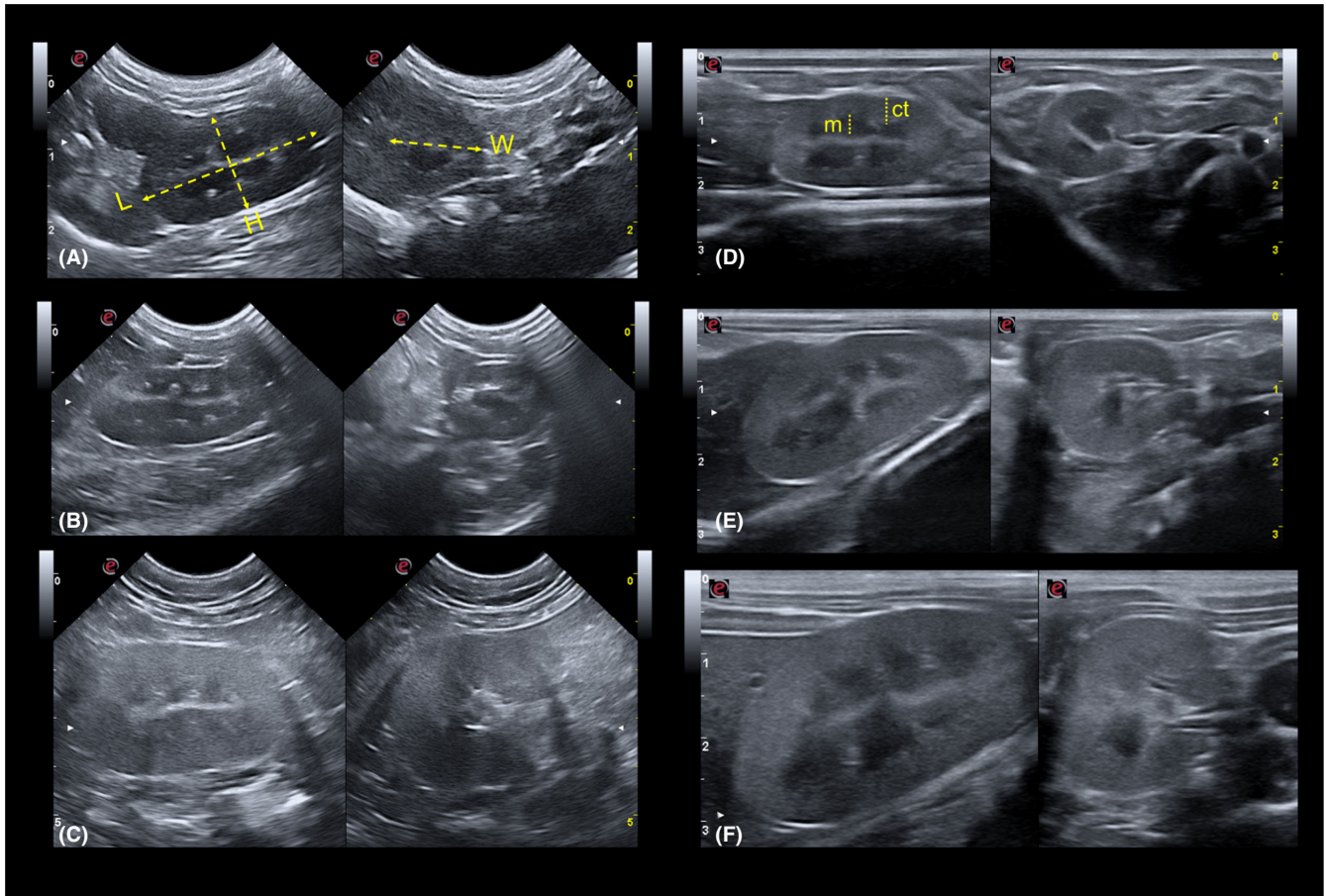


FIGURE 1 Ultrasonographic images demonstrating sagittal and transverse sections for measuring length (L) and height (H) were measured using sagittal scans, and renal width (W) Cortex (ct) and Medullary Pyramid (m) by age group [infant (A and D), juvenile (B and E), and adult (C and F)] in *Alouatta caraya* and *Sapajus apella*, respectively. Note increased thickness and echogenicity of the cortical region, more evident in adult animals of *A. caraya*

3 | RESULTS

3.1 | Ultrasound exams

None of the animals had alterations in kidney topography. The right kidney was more cranial than the left, and both kidneys were characterized by a homogeneous cortical echotexture with preserved corticomedullary differentiation, and a cortex/medulla thickness ratio of approximately 2:1. In both species, the medulla was more evident due to a lower echogenicity in infants. We observed an increase in the thickness and echogenicity of the cortical region with advancing age, which was more evident in adult *A. caraya* (Figure 2).

3.2 | Kidney biometrics

The biometric parameters of the right and left kidneys for each species are summarized per age group in Table 1. There were no significant differences between the measurements of the right and left kidneys for neither *A. caraya* length, $t(39) = 0.003$, $P = .99$, width,

$t(39) = 0.33$, $P = .73$, height, $t(39) = 1.25$, $P = .21$, volume, $t(39) = 0.68$, $P = .49$, cortex/medulla, $t(39) = 1.25$, $P = .21$, nor for *S. apella* length, $t(41) = 0.21$, $P = .83$, width, $t(41) = 0.52$, $P = .60$, height, $t(41) = 1.08$, $P = .28$, volume ($U = 192$, $P = .48$), and cortex/medulla, $t(39) = 1.09$, $P = .27$.

The mean growth from infant to adult classes was more pronounced in *A. caraya* than in *S. apella* for all biometric parameters: length = 54.53% and 37.01%; height = 47.64% and 43.03%; width = 55.43% and 22.12%; and volume = 264.52% and 147.26%, respectively.

3.3 | Absolute renal volume

The best model that tested absolute kidney volume as a response factor revealed significant effects of species, sex, and age. *S. apella* had a lower mean renal volume (GLM: -0.02 ± 0.006 , $t = -3.52$, $P < .001$) than *A. caraya* (Figure 2A), and the mean renal volume was greater in males (GLM: 0.01 ± 0.006 , $t = 2.35$, $P = .02$) than in females (Figure 2B). Moreover, we observed a significant, positive

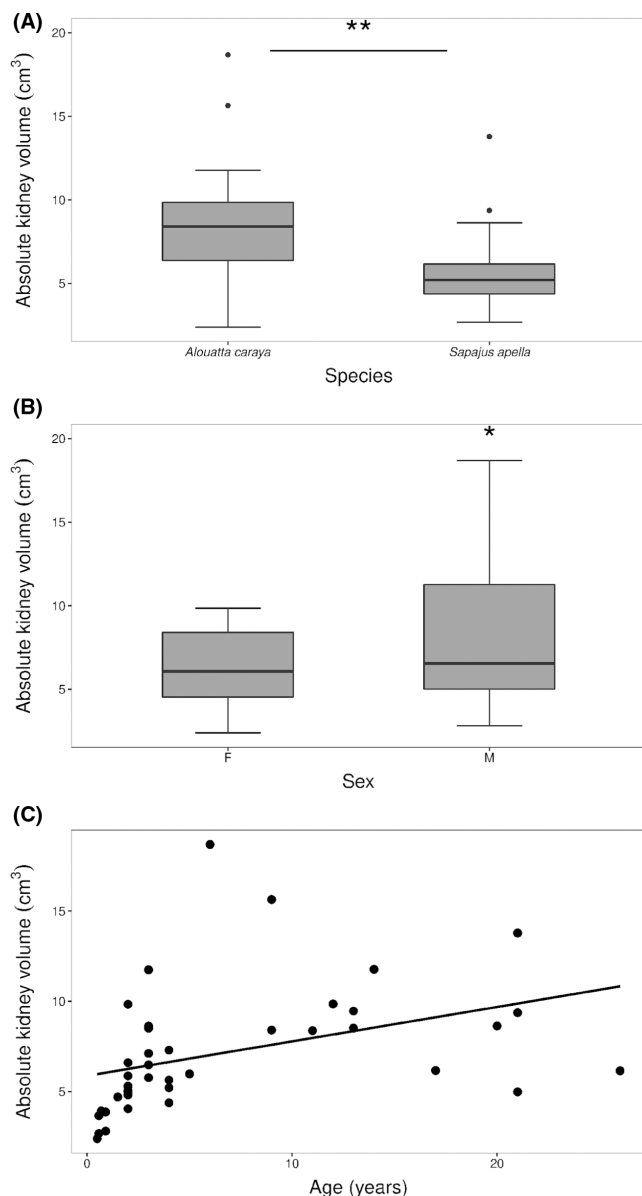


FIGURE 2 Effect of species (A), sex (F—Female; M—Male) (B), and age (C) on the absolute renal volume in *Alouatta caraya* ($N = 21$) and *Sapajus apella* ($N = 21$), housed at the National Primate Center, district of Ananindeua, Pará, Brazil, January 2020. * $P < .05$, ** $P < .01$

relationship between volume and age (GLM: 0.001 ± 0.0004 , $t = 3.90$, $P = .0004$), controlling for species and sex (Figure 2C).

3.4 | Relative kidney volume

We built a second model using the relative kidney volume as response factor, initially testing the same fixed factors as in the previous model. The best model revealed a significant effect of species, with a higher relative volume in *S. apella* (GLM: 0.32 ± 0.048 , $t = 6.74$, $P < .001$) than in *A. caraya* (Figure 3). There was no effect of age and sex in none of the models, so these factors were excluded from the final model.

3.5 | Red blood cells, creatinine, and urea

Finally, we built three additional models to investigate the effect of RBC, creatinine, and urea on sex, age, species, and renal relative volume. For the model including RBC as a response factor, we observed a significant negative effect of age (GLM: -0.03 ± 0.01 , $t = -2.3$, $P = .03$) (Figure 4A). We were unable to test the effect of sex due to heteroscedasticity ($F_{1,38} = 6.07$, $P = .02$), but we found a strong effect of species (GLM: 1.15 ± 0.24 , $t = 4.77$, $P < .0001$), with higher RBC in *S. apella* ($5.60 \pm 0.49 \times 10^6/\text{mm}^3$) than in *A. caraya* ($4.37 \pm 0.58 \times 10^6/\text{mm}^3$) (Figure 4B).

When testing creatinine as a response factor, the best model showed a significant, positive correlation with body mass (GLM: 0.04 ± 0.01 , $Z = 2.60$, $P = .01$; Figure 5A). We also observed an interaction between species and age, with a steeper negative relationship between creatinine and age only in *S. apella* (GLM: -0.03 ± 0.01 , $Z = -3.33$, $P = .002$; Figure 5B). The models for urea as a predictor did not differ from the null model, indicating no effect of body mass, species, sex, or age on urea levels. Mean relative renal volume did not influence any of the blood parameters.

4 | DISCUSSION

The ultrasound appearance of the kidneys in both species was similar to that described previously in other Platyrrhines, including *A. fusca*,²⁸ *S. apella*,^{29,30} *A. azarae infulatus*,¹⁰ and *S. collinsi*,²⁶ in which both kidneys had an elliptical shape, echogenicity and homogeneous cortical echotexture with preserved corticomedullary differentiation. One study in *C. jacchus*, reported a poor corticomedullary distinction in the kidneys,²⁵ which could have been due to the small size of these primates. Other studies reported a triangular shape when evaluating the left kidney in *Saguinus ursulus*³⁴ and in some *M. fascicularis* individuals.³⁵ This emphasizes the importance of characterizing the kidney anatomy for each species.

We found no differences between the right and left kidneys for all biometric parameters, which is similar to previous studies in *S. apella*^{29,30} and *Macaca mulatta*,⁷ but contrasts with studies in other species. For instance, studies in the platyrrhine primates *A. azarae infulatus*⁸ and in *C. jacchus*²⁵ reported that the left kidney had a greater height and length than the right kidney. Other studies in the catarrhines *M. fascicularis*^{35,36} and *Chlorocebus sabaeus*,³⁷ as well as in the platyrrhine *S. collinsi*,²⁶ reported the opposite trend, with a greater volume or length in the right kidney when compared to the left. The inconsistency in the literature may be associated with methodological differences, but it may be related to interspecies differences, with no clear trend between platyrrhine and catarrhine species.

The higher growth rate of biometric parameters observed in *A. caraya* in relation to *S. apella* may be associated with the fact that the former reaches a higher body mass than the latter, with approximately 5–7.8 kg in adult *A. caraya*¹⁴ and 3–4 kg in *S. apella*.^{18,19} Although we did not find an effect of body mass on renal biometry,

TABLE 1 Ultrasonographic measurements of the right and left kidneys (mean \pm standard deviation) between the age groups of *A. caraya* and *Sapajus apella*, housed at the National Primate Center, district of Ananindeua, Pará, Brazil, January 2020

Species (N)	Age group (n)	Right kidney					Left kidney				
		Length (cm)	Height (cm)	Width (cm)	Cortex/medulla	Volume (cm ³)	Length (cm)	Height (cm)	Width (cm)	Cortex/medulla	Volume (cm ³)
<i>Alouatta caraya</i> (N = 21)	Infant (n = 3)	2.71 \pm 0.37	1.32 \pm 0.08	1.59 \pm 0.14	1.61 \pm 0.05	3.01 \pm 0.72	2.67 \pm 0.29	1.38 \pm 0.03	1.57 \pm 0.16	1.43 \pm 0.08	3.04 \pm 0.58
	Juvenile (n = 10)	3.73 \pm 0.42	1.64 \pm 0.18	2.13 \pm 0.21	1.68 \pm 0.48	6.94 \pm 1.73	3.63 \pm 0.24	1.75 \pm 0.25	2.39 \pm 0.36	1.57 \pm 0.29	8.16 \pm 2.85
	Adult (n = 8)	4.09 \pm 0.36	2.02 \pm 0.37	2.40 \pm 0.37	1.88 \pm 0.66	10.68 \pm 4.03	4.22 \pm 0.31	1.97 \pm 0.46	2.52 \pm 0.45	1.62 \pm 0.54	11.40 \pm 4.37
<i>Sapajus apella</i> (N = 21)	Infant (n = 4)	2.52 \pm 0.20	1.35 \pm 0.04	1.79 \pm 0.37	1.83 \pm 0.33	3.21 \pm 0.71	3.03 \pm 0.31	1.22 \pm 0.16	1.74 \pm 0.19	1.63 \pm 0.07	3.43 \pm 0.99
	Juvenile (n = 10)	3.35 \pm 0.17	1.61 \pm 0.08	1.92 \pm 0.11	1.67 \pm 0.11	5.45 \pm 0.62	3.23 \pm 0.31	1.61 \pm 0.11	1.79 \pm 0.22	1.67 \pm 0.23	4.90 \pm 1.06
	Adult (n = 7)	3.81 \pm 0.37	1.87 \pm 0.20	2.19 \pm 0.33	1.74 \pm 0.23	8.46 \pm 2.72	3.79 \pm 0.40	1.80 \pm 0.29	2.13 \pm 0.31	1.67 \pm 0.23	7.95 \pm 3.43

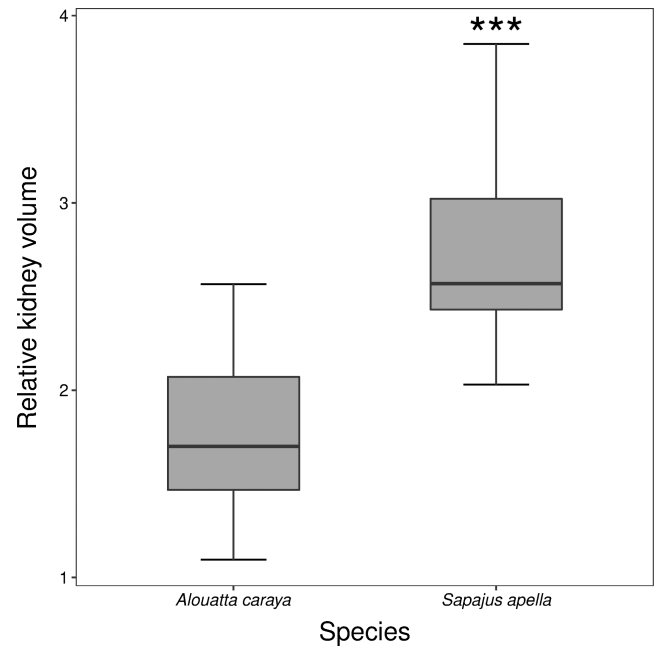


FIGURE 3 Relative renal volume in *Alouatta caraya* and *Sapajus apella*, housed at the National Primate Center, district of Ananindeua, Pará, Brazil, January 2020. *** $P < .001$

we found a greater absolute kidney volume in *A. caraya* than *S. apella* and in adult males in both species. Previous studies have reported a positive correlation between body mass and renal biometric variables in *A. azarae infulatus*,⁸ *S. collinsi*,²⁶ and *M. mulatta*.⁷ In addition, renal volume in *M. fascicularis* was positively correlated with body mass,^{35,36} and in humans the renal length was positively correlated with body mass and body mass index.³⁸ The lack of significance between body mass and absolute renal volume in this study was probably related to our multi-factorial analyses, and shows that species, sex, and age were better predictors of kidney volume than body mass.

The effect of sex in the literature is also mixed. One study in adult and elder humans (18–80 years old) found no sex differences in renal length or cortical thickness.³⁸ A post-mortem study in *M. fascicularis* showed that the absolute kidney mass was greater in older than in young animals of the same sex, but this effect was more pronounced in males.²⁷ In *S. collinsi*, the total kidney volume had an interaction between body mass and sex, being greater in heavier males.²⁶ In *A. azarae infulatus*, no differences in biometrics parameters were observed between males and females.⁸ These interspecies differences are likely associated with the role of sexual dimorphism in the evolution of primate societies. *A. a. infulatus* are monogamous and characterized by little or no sexual dimorphism, given that males do not need to compete for accessing females,³⁹ and no sex differences are expected in absolute renal volume. In contrast, sexual dimorphism is present in *S. collinsi* and *M. fascicularis*,³⁹ as well as in both species examined in this study.⁴⁰ Consequently, males in these species have larger body mass than females, which reflects their multi-male/multi-female social system.^{39,41} Thus, sex differences in morphophysiology appears to be

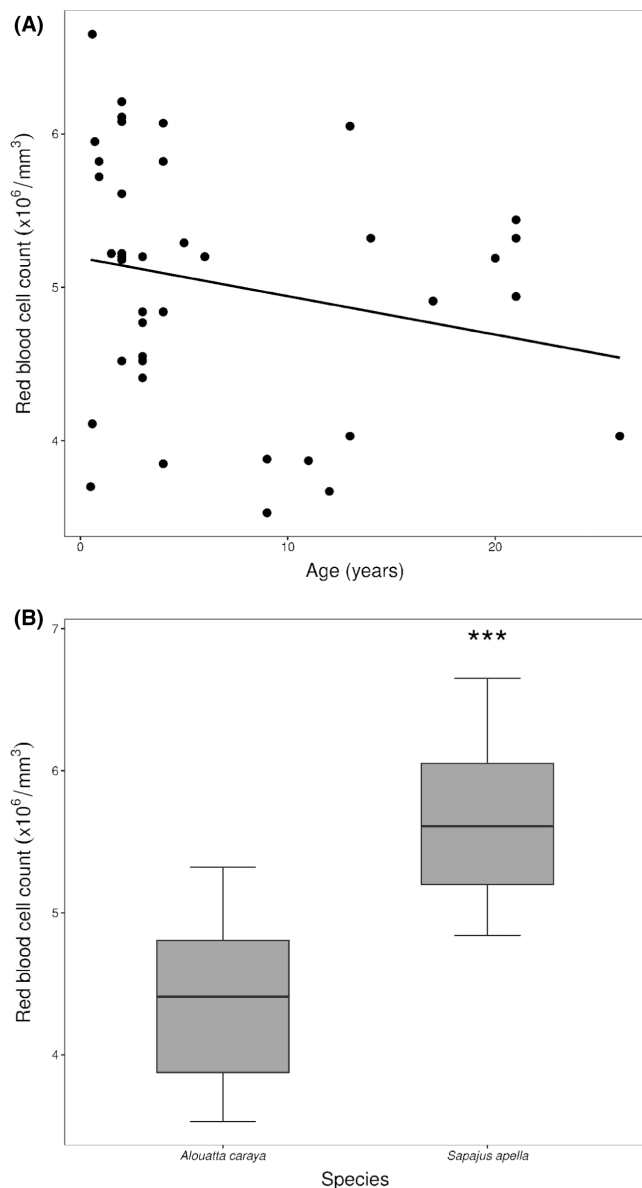


FIGURE 4 Effect of age (A) and species (B) on red blood cell count in howler monkey (*Alouatta caraya*) and capuchin monkey (*Sapajus apella*), housed at the National Primate Center, district of Ananindeua, Pará, Brazil, January 2020. *** $P < .001$

a characteristic of polygamous primate society, including what was observed for absolute renal volume.

The cortex/medulla ratio in both species was approximately 2:1 for all age groups. A similar result was described in another study in *S. apella*,²⁹ but it differs from the renal pattern previously described by ultrasound and postmortem evaluation in *A. fusca* (1:1).²⁸ In the catarrhine *M. fascicularis*, one study with histological and postmortem evaluations reported the cortex/medulla ratio as approximately 1:1 and associated this finding to the smaller size of the renal papilla in this species, which makes the medulla slightly larger than the cortex,²⁷ but a recent study using ultrasound in the same species reported a smaller cortex/medulla ratio (1:4).³⁵ Postmortem evaluation is considered a more accurate method to evaluate the

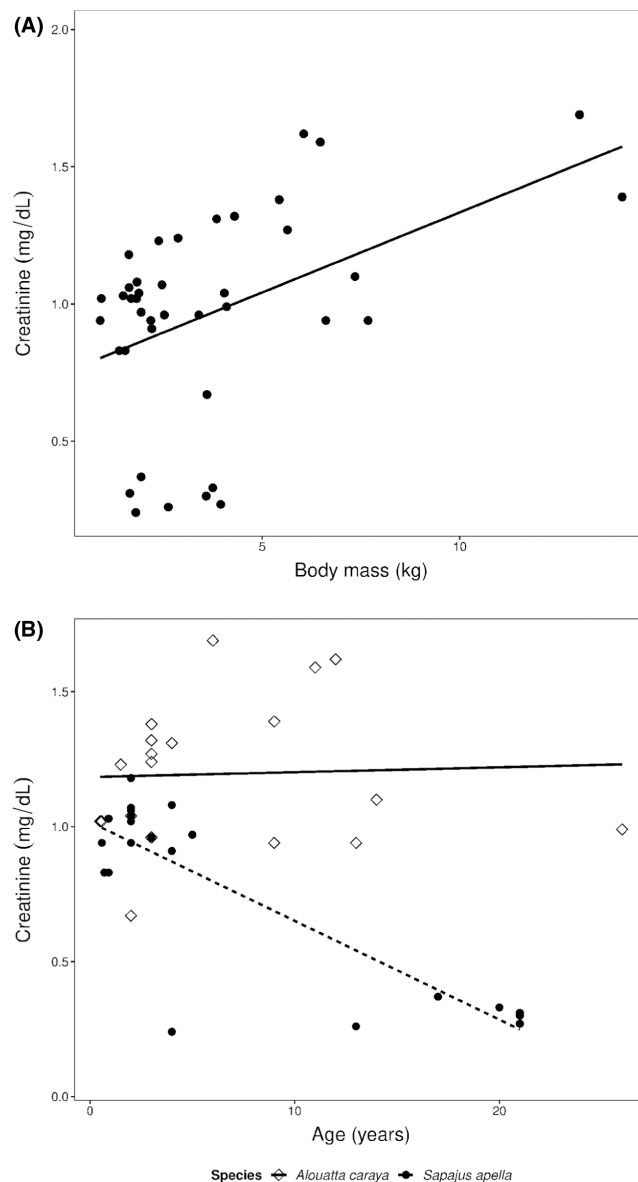


FIGURE 5 Effect of body mass (A) and the interaction between species and age (B) on creatinine values in *Alouatta caraya* and *Sapajus apella*, housed at the National Primate Center, district of Ananindeua, Pará, Brazil, January 2020

cortex/medulla ratio than ultrasound, thus the inconsistency in the literature may be related to specie-specific or methodological differences. Comparative studies using postmortem evaluation are needed to clarify if there are species differences in the cortex ratio within primates.

With regard to changes in echogenicity, our ultrasound images revealed an age-related increase in the echogenicity of the cortical region compared to the medullar area in both species. The anechoic aspect of the renal medulla in young animals has been reported in humans and animals^{42,43} and has been associated with the larger volume of medulla in the infants and the presence of dilute urine in the tubule.⁴² Although echogenicity was quantified subjectively in this study, the age-related increase in echogenicity

was more evident in *Alouatta caraya*, which is visible by the lower degree of corticomedullary contrast in adults. One possible mechanism related to these changes may be a decline in prominence of medullary pyramids with age,⁴² but additional studies are needed to elucidate this mechanism. Nonetheless, this finding suggests that the aging process in *A. caraya* is faster than in *S. apella* and may be one of the reasons by which the latter species have a remarkable longevity than expected for its body size. Similarly, corticomedullary contrast did not change with age in humans,⁴⁴ which supports this hypothesis. However, our study is limited by the lack of a quantitative echogenic index to accurately assess renal echogenicity, that could detect renal changes.⁴⁵ Further comparative studies including other species with different life-history traits would be extremely relevant to confirm this hypothesis.

Although the absolute renal volume was greater in *A. caraya* as expected, the relative renal volume was greater in *S. apella*. This indicates that the latter has a larger kidney for their expected body mass, and it may explain the lack of correlation between absolute kidney volume and body mass in our study. Within the Primates order, the genus *Sapajus* has the second highest encephalization quotient (brain/body mass ratio), lower only than in humans.⁴⁶ This particularity of *Sapajus* indicates that these animals, like humans, undergo rapid neurological changes during the first years of life.⁴⁷ Consequently, some hypotheses have linked this trait with high cognitive abilities demonstrated by this genus.^{47,48} In contrast, the genus *Alouatta* has a relatively small brain size compared to *Sapajus*.⁴⁹ The brain size differences have been associated with social factors such as group size as a potential factor that demands high cognition,^{50,51} or with diet, proposed by Parker and Gibson⁵² and Milton⁵³ in the "Ecological-Intelligence Hypothesis" that frugivorous primates, such as the *Sapajus* genus, evolved larger brains due to their higher energetic intake when compared to folivorous primates, such as the genus *Alouatta*.^{49,54} Our data show that the brain is not the only organ larger than expected in *Sapajus*, and it suggests that this genus might have undergone dwarfism, with a reduction in the body size while maintaining important metabolic organs unaltered. Another hypothesis is that kidney enlargement in this genus co-evolved with their high encephalization quotient, given that a larger brain might increase oxygen demands.^{55,56} Kidneys are important sources of RBC, which are necessary for oxygen transportation in the body.² Since the brain tissue is metabolically expensive to grow and to maintain,⁵⁵ a larger kidney may have evolved to attend those demands.

This hypothesis is supported by the species differences in RBC count in the present work and in a previous study in wild populations⁵⁷ that showed higher RBC count in *Sapajus libidinosus* compared to *A. caraya*. Although we were unable to compare RBC count between sexes due to heteroscedasticity, previous studies have reported a greater RBC count in males than females in innumerable primate species, including *S. apella*,⁵⁸ *S. libidinosus*,⁵⁹ *Alouatta guariba clamitans*,⁶⁰ *A. azarae infulatus*¹⁰ and *S. collinsi*.¹¹ These sex differences have been associated with the stimulatory effect of testosterone on erythropoiesis, and the inhibitory effect of estrogen.⁶¹⁻⁶³

We also observed an aging effect on RBC count in both species, suggesting a decline in hematopoiesis in older individuals. Similar results have been reported in *Sapajus libidinosus*⁵⁹ but contrasts with another study in *S. apella* in which adult males had a higher RBC count than adult females and juvenile males.⁵⁸ This contrast may be related to differences in the age ranges of the subjects studied. Testosterone may have a strong effect in erythropoiesis in younger than older males. Age-related changes in the hematopoietic system have been characterized by intrinsic changes in erythroid progenitor cells, in the cell hematopoietic microenvironment and by humoral changes, such as individual response to erythropoietin, testosterone, growth hormone, and inflammation.⁶⁴

Relative renal volume did not correlate with any of the laboratory tests, probably because these parameters accuse changes only after the kidney function is compromised.^{9,65} Similarly, in humans, despite a significant decline in creatinine clearance with aging, a corresponding reduction in renal length was not observed.³⁸ Alternatively, kidney tests may be related to the number of nephrons instead of the renal volume. In humans and NHP, nephrogenesis occurs prenatally, and the kidney development after birth is limited to the differentiation of the nephrons already present.^{3,66,67} Therefore, our data showed that kidney function tests do not correlate with renal volume, but whether a reduction in renal volume precedes nephropathologies remains to be investigated.

We found that creatinine had a significant, positive increase with body mass, and an interaction between species and age, indicating an apparent negative relationship with age in *S. apella*, but not in *Alouatta caraya*. The effect of body mass was similar to a previous report in *S. collinsi*²⁶ and is associated with the fact that creatinine is produced in the muscles.⁶⁸ However, the effect of age found in our study contrasts with those found in the other study with *S. apella*⁶⁸ and other primates, including *M. fascicularis*⁶⁹ and *A. azarae infulatus*¹⁰ in which serum creatinine was higher in adult animals and in males. This contrast could be related to species differences in creatinine clearance rates. In humans, an increase in creatinine levels in elderly patients has been associated with a decline in clearance rates,³⁸ but further studies are needed to investigate species differences in creatinine clearance rates. Alternatively, the interaction found between these species could be related to the age ranges of our subjects. Primates of the genus *Sapajus* can live up to 50 years in captivity, but their mean lifespan in the wild is of approximately 25 years.⁷⁰ Therefore, *S. apella* over 25 years old may experience a decline in muscle mass that could contribute to their reduced survival chances in the wild. Our sample size included four *S. apella* and only one *A. caraya* over 20 years-old, which may explain the interaction observed in our findings. Further data on muscle mass in these animals is needed to confirm this hypothesis.

We found no effect of species, sex, age, or body mass on urea concentrations. The literature on this marker in NHP is mixed. In *S. collinsi*, there was no influence of sex, age, or body mass on urea concentrations.²⁶ In contrast, another study in the same species found higher urea concentrations in females than in males.¹¹ In *M. fascicularis*, one study showed age-related differences, with lower

concentrations in adults, but no sex differences.²⁷ In *A. azarae infulatus*, urea was significantly higher in males, but unrelated to age.¹⁰ In addition to intrinsic factors, extrinsic factors such as diet, or kidney diseases can influence urea concentrations,⁷¹ which may explain the discrepancies reported in the literature.

In general, the two species evaluated showed an increase in all renal biometric parameters with age. *A. caraya* showed greater growth rate when compared to *S. apella* and greater absolute renal volume. However, *S. apella* had greater relative renal volume, which could indicate higher RBC demands, as supported by the higher RBC production in this species. RBC and creatinine values were also influenced by age and body mass, respectively, and urea was not correlated with age, sex, or body mass in either species. The results described are useful for kidney assessment by ultrasonographic evaluation in different age groups in the two species. They can help us to understand the postnatal renal growth pattern in two neotropical primates and provide evolutionary insights on aging processes and metabolism among neotropical primates.

ACKNOWLEDGMENTS

The authors thank the staff from the National Primate Center (CENP) and Federal Rural University of the Amazon (UFRA) for providing animal care and for their assistance during data collection. This study was funded by the National Council of Technological and Scientific Development (CNPq Nos 305821/2017-2, 400881/2019-5 and 316750/2021-2), the Coordination for the Improvement of Higher Education Personnel (CAPES-Procad Amazônia No. 21/2018), the Wenner-Gren Foundation (No. 10088), and the National Science Foundation (Award No. 212357).

CONFLICT OF INTEREST

The authors declare that there is no conflict of interest regarding the publication of this article.

DATA AVAILABILITY STATEMENT

The datasets during and/or analyzed during the current study are available from the corresponding author on reasonable request.

ORCID

Gessiane Pereira da Silva  <https://orcid.org/0000-0002-0943-5487>

Leandro Nassar Coutinho  <https://orcid.org/0000-0002-9579-3052>

REFERENCES

- Fisher JW, Koury S, Ducey T, Mendel S. Erythropoietin production by interstitial cells of hypoxic monkey kidneys. *Br J Haematol*. 1996;95:27-32.
- Wallace MA. Anatomy and physiology of the kidney. *AORN J*. 1998;68:799-820.
- Little MH, AP MM. Mammalian kidney development: principles, progress, and projections. *Cold Spring Harb Perspect Biol*. 2012;4:a008300. doi:10.1101/cshperspect.a008300
- Wadei HM, Textor SC. The role of the kidney in regulating arterial blood pressure. *Nat Rev Nephrol*. 2012;8:602-609.
- Saint-Faust M, Boubred F, Simeoni U. Renal development and neonatal adaptation. *Am J Perinatol*. 2014;31:773-780.
- Hommos MS, Glasscock RJ, Rule AD. Structural and functional changes in human kidneys with healthy aging. *J Am Soc Nephrol*. 2017;28:2838-2844.
- Wang H, Feng Q, Li C, Zhang H, Peng Y. Ultrasonographic study of hemodynamics and CEUS in the rhesus monkey kidney. *Exp Anim*. 2021;71:116-122. doi:10.1538/expanim.20-0194
- Lins FL, Monteiro FO, Takeshita RS, et al. Renal evaluation of *Aotus azarae infulatus* by ultrasonography and serum chemistry profile. *Am J Primatol*. 2012;74:482-490.
- Denic A, Glasscock RJ, Rule AD. Structural and functional changes with the aging kidney. *Adv Chronic Kidney Dis*. 2016;23:19-28.
- Takeshita RS, Monteiro FO, de Miranda Lins e Lins FL, et al. Hematological, hepatic, and renal evaluation in *Aotus azarae infulatus*. *J Med Primatol*. 2011;40:104-110.
- Cardoso DL, Costa SM, Muniz JAPC, Castro PHG, Costa JB, Dias HLT. Avaliação do perfil hematológico e bioquímico de macacos de cheiro (*Saimiri collinsi*) cativos no Centro Nacional de Primatas no Estado do Pará. *Braz J Anim Environ Res*. 2021;4:2764-2776.
- Steensma DP, Tefferi A. Anemia in the elderly: how should we define it, when does it matter, and what can be done? *Mayo Clin Proc*. 2007;82:958-966.
- Groarke EM, Young NS. Aging and hematopoiesis. *Clin Geriatr Med*. 2019;35:285-293.
- Svoboda WK, Malanski LS, Shiozawa MM, et al. Dados biométricos de *Alouatta caraya* de vida livre de ilhas do alto rio Paraná, Porto Rico, PR. XXVI Congresso Brasileiro de Zoologia. Anais do XXVI Congresso Brasileiro de Zoologia. Sociedade Brasileira de Zoologia. CD-ROM; 2006.
- Calegario-Marques C, Bicca-Marques JC. Reprodução de *Alouatta caraya* Humboldt, 1812 (Primates, Cebidae). In: Yamamoto ME, Sousa MBC, eds. *A primatologia no Brasil*. 4ª ed. Editora da Universidade Federal do Rio Grande do Norte; 1993:51-66.
- Kowalewsky MM, Zunino GE. Birth seasonality in *Alouatta caraya* in northern Argentina. *Int J Primatol*. 2004;25:383-400.
- Rumiz DI. *Alouatta caraya*: population density and demography in northern Argentina. *Am J Primatol*. 1990;21:279-294.
- Fleagle JG, Mittermeier RA. Locomotor behavior, body size, and comparative ecology of seven Surinam monkeys. *Am J Phys Anthropol*. 1980;52:301-314.
- Smith RJ, Jungers WL. Body mass in comparative primatology. *J Hum Evol*. 1997;32:523-559.
- Ross C, Jones KE. Socioecology and the evolution of primate reproductive rates. In: Lee PC, ed. *Comparative primate socioecology*. Cambridge University Press; 1999:73-110.
- Rylands AB, Mittermeier RA. Species account of *Sapajus apella*. In: Mittermeier RA, Rylands AB, Wilson DE, eds. *Handbook of the mammals of the world, vol. 3 – Primates*. Lynx Edicions; 2013:402-403.
- Cardoso DL, Guimarães DAA, Ferreira MAP, et al. Reproductive biology of owl (*Aotus* spp.) and capuchin (*Sapajus* spp.) monkeys. *Anim Reprod Sci*. 2021;227:106732. doi:10.1016/j.anireprosci.2021.106732
- Fragaszy DM, Visalberghi E, Fedigan LM. *The complete Capuchin: the biology of the genus Cebus*. Cambridge University Press; 2004.
- Tardif SD, Mansfield KG, Ratnam R, Ross CN, Ziegler TE. The marmoset as a model of aging and age-related diseases. *ILAR J*. 2011;52:54-65.
- Wagner WM, Kirberger RM. Transcutaneous ultrasonography of the abdomen in the normal common marmoset (*Callithrix jacchus*). *Vet Radiol Ultrasound*. 2005;46:251-258.
- Lins FLM, Mayor P, Silva Filho E, et al. Renal biochemistry variables and ultrasonographic imaging in healthy Squirrel monkeys (*Saimiri collinsi*). *Vet Clin Pathol*. 2017;46:126-131.

27. Chamanza R, Naylor SW, Carreira V, et al. Normal anatomy, histology, and spontaneous pathology of the kidney, and selected renal biomarker reference ranges in the cynomolgus monkey. *Toxicol Pathol.* 2019;4:612-633.
28. Sartor R, Müller TR, Mamprim MJ, et al. Abdominal ultrasonography of the healthy howler monkey (*Alouatta fusca*). *Vet Med Sci.* 2017;3:32-39.
29. Alves FR, Costa FB, Arouche MMS, et al. Ultrasonographic evaluation of the urinary system, liver and uterus of *Cebus apella* monkey. *Pesq Vet Bras.* 2007;27:377-382.
30. Carandina da Silva L, Machado VMV, Teixeira CR, et al. Renal evaluation with B-mode and Doppler ultrasound in captive tufted capuchins (*Sapajus apella*). *J Med Primatol.* 2015;45:28-33.
31. Rimoli J, Nantes RS, Júnior AEL. Diet and activity patterns of black Howler Monkeys *Alouatta caraya* (Humboldt, 1812, primates, atelidae) in Ecotone Cerrado-Pantanal in the left bank of Aquidauana River, Mato Grosso do Sul, Brazil. *Oecol Aust.* 2012;16:933-948.
32. Levene H. Robust tests for equality of variances. In: Olkin I, ed. *Contributions to probability and statistics*. Vol 1. Stanford University Press; 1960:278-292.
33. Burnham KP, Anderson DR. *Model selection and multimodel inference. A practical information-theoretic approach*. Springer; 2002:488.
34. Borges LB, Pereira AKF, Silva WBD, Monteiro FOB, Coutinho LN. Abdominal ultrasound in *Saguinus ursulus*. *J Med Primatol.* 2020;49:307-314.
35. Cardenio P, Acorda J, Lastica-Ternura E. Ultrasonographic features of liver, gallbladder, spleen, kidneys and urinary bladder of rescued long-tailed macaques, *Macaca fascicularis*. *Turk J Vet Anim Sci.* 2020;44:1063-1069.
36. Gaschen L, Menninger K, Schuurman HJ. Ultrasonography of the normal kidney in the cynomolgus monkey (*Macaca fascicularis*): morphologic and Doppler findings. *J Med Primatol.* 2000;29:76-84.
37. Amory JT, Du Plessis WM, Beierschmitt A, Beeler-Marfisi J, Palmour RM, Beths T. Abdominal ultrasonography of the normal St. Kitts vervet monkey (*Chlorocebus sabaeus*). *J Med Primatol.* 2012;42:28-38.
38. El-Reshaid W, Abdull-Fattah H. Sonographic assessment of renal size in healthy adults. *Med Princ Pract.* 2014;23:432-436.
39. Ford SM. Taxonomy and distribution of the owl monkey. In: Baer JF, Weller RE, Kakoma I, eds. *Aotus: the owl monkey*. Academic Press; 1994:1-57.
40. Di Fiore A, Campbell CJ. The atelines: variation in ecology, behavior, and social organization. In: Campbell CJ, Fuentes AF, MacKinnon KC, Panger M, Bearder S, eds. *Primates in perspective*. 2^a ed. Oxford University Press; 2010:155-185.
41. Plavcan JM, van Schaik CP. Intrasexual competition and body weight dimorphism in anthropoid primates. *Am J Phys Anthropol.* 1999;103:37-68.
42. Vade A, Lau P, Smick J, Harris V, Ryva J. Sonographic renal parameters as related to age. *Pediatr Radiol.* 1987;17:212-215.
43. Finn-Bodner ST. The kidneys. In: Cann C, Hunsberger S, Magarle MD, Magee RD, eds. *Practical veterinary ultrasound*, 1^a ed. Williams & Wilkins; 1995:156-198. 329 p.
44. Noda Y, Kanki A, Yamamoto A, et al. Age-related change in renal corticomedullary differentiation: evaluation with noncontrast-enhanced steady-state free precession (SSFP) MRI with spatially selective inversion pulse using variable inversion time. *J Magn Reson Imaging.* 2014;40:79-83.
45. Manley JA, O'Neill WC. How echogenic is echogenic? Quantitative acoustic of the renal cortex. *Am J Kidney Dis.* 2001;37:706-711.
46. Roth G, Dicke U. Evolution of the brain and intelligence in primates. *Prog Brain Res.* 2012;195:413-430.
47. Phillips KA, Sherwood CC. Cortical development in brown capuchin monkeys: a structural MRI study. *Neuroimage.* 2008;43:657-664.
48. Ottoni EB, Izar P. Capuchin monkey tool use: overview and implications. *Evol Anthropol.* 2008;17:171-178.
49. Hartwig W, Rosenberger AL, Norconk MA, Owl MY. Relative brain size, gut size, and evolution in new world monkeys. *Anat Rec.* 2011;294:2207-2221.
50. Dunbar RIM. The social brain hypothesis. *Evol Anthropol.* 1998;6:178-190.
51. Dunbar RIM. The social brain hypothesis and its implications for social evolution. *Ann Hum Biol.* 2009;36:562-572.
52. Parker ST, Gibson KR. Object manipulation, tool use and sensorimotor intelligence as feeding adaptations in Cebus monkeys and great apes. *J Hum Evol.* 1977;6:623-641.
53. Milton K. Foraging behavior and the evolution of primate intelligence. In: Byrne RW, Whiten A, eds. *Machiavellian intelligence: social expertise and the evolution of intellect in monkeys, apes, and humans*. Oxford University Press; 1998:285-305.
54. DeCasien A, Williams S, Higham J. Primate brain size is predicted by diet but not sociality. *Nat Ecol Evol* 1. 2017;1:1-7. doi:10.1038/s41559-017-0112
55. Mink JW, Blumenschine RJ, Adams DB. Ratio of central nervous system to body metabolism in vertebrates: its constancy and functional basis. *Am J Physiol.* 1981;241:R203-R212.
56. Navarrete A, van Schaik CP, Isler K. Energetics and the evolution of human brain size. *Nature.* 2011;480:91-94.
57. Ribeiro CLB, Melo-Reis PR, Lemes SR, Araújo LA, Silva-Júnior NJ. Análise hematológica de macacos-prego (*Sapajus libidinosus* Spix, 1923) e bugios (*Alouatta caraya* Humboldt, 1812) de vida livre no sul do estado de Tocantins, Brasil. *R Bras Bioci.* 2015;13:110-114.
58. Larsson MHMA, Birgel EH, Benesi FJ, et al. Hematological values of *Cebus apella* anesthetized with ketamine. *Braz J Vet Res Anim Sci.* 1999;36:131-135.
59. Ferreira AF, Queiroga FL, Mota RA, et al. Hematological profile of captive bearded capuchin monkeys (*Sapajus libidinosus*) from Northeastern Brazil. *Cienc Rural.* 2018;48:1-7. doi:10.1590/0103-8478cr20180065
60. Gonçalves GHP, de Souza Junior JC, Pitz HS, Peruchi AR, Branco FS, Hirano ZMB. Hematological and serum biochemistry data on southern brown howler monkeys (*Alouatta guariba clamitans*) in captivity in Brazil. *J Med Primatol.* 2019;48:313-319.
61. Jain NC. *Essentials of veterinary hematology*. Lippincott Williams & Wilkins; 1993:420.
62. Wirz A, Truppa V, Riviello MC. Hematological and plasma biochemical values for captive tufted capuchin monkeys (*Cebus apella*). *Am J Primatol.* 2008;70:463-472.
63. Favareto AD, Costa MM, Grumann MR, et al. Perfil hematológico e bioquímico de macacos-prego (*Cebus* spp.) mantidos em cativeiro. *Braz J Vet Med.* 2016;38:406-412.
64. Price EA. Aging and erythropoiesis: current state of knowledge. *Blood Cells Mol Dis.* 2008;41:158-165.
65. Gekle M. Kidney and aging – a narrative review. *Exp Gerontol.* 2017;87:153-155.
66. Batchelder CA, Lee CC, Martinez ML, Tarantal AF. Ontogeny of the kidney and renal developmental markers in the rhesus monkey (*Macaca mulatta*). *Anatomical record (Hoboken, N.J.: 2007).* 2010;293:1971-1983.
67. Schuh MP, Alkhudairy L, Potter A, et al. The rhesus macaque serves as a model for human lateral branch nephrogenesis. *J Am Soc Nephrol.* 2021;32:1097-1112.
68. Larsson MHMA, Lucas SRR, Mirandola RMS, Lazaretti P, Fedulho JDL, Guimarães MAVB. Valores de referência das provas de funções hepática, renal e de alguns eletrólitos em *Cebus apella*, anestesiados com cetamina. *Cienc Rural.* 1997;27:257-262.

69. Xie L, Xu F, Liu S, et al. Age- and sex-based hematological and biochemical parameters for *Macaca fascicularis*. *PLoS One*. 2013;8:e64892. doi:[10.1371/journal.pone.006489](https://doi.org/10.1371/journal.pone.006489)
70. Bronikowski AM, Cords M, Alberts SC, et al. Female and male life tables for seven wild primate species. *Sci Data*. 2016;3:160006. doi:[10.1038/sdata.2016.6](https://doi.org/10.1038/sdata.2016.6)
71. Thrall MA. Considerações sobre interpretação de resultados laboratoriais. In: Thrall MA, Campbell TW, Denicola D, et al., eds. *Hematologia e bioquímica clínica veterinária*. 2nd ed. Rocca; 2014:688.

How to cite this article: da Silva GP, de Souza Pereira TH, Imbeloni AA, et al. Effect of age and sex in renal function by ultrasound and serum chemistry in two primate species (*Alouatta caraya* and *Sapajus apella*). *J Med Primatol*. 2022;00:1-11. doi: [10.1111/jmp.12599](https://doi.org/10.1111/jmp.12599)