

ORIGINAL ARTICLE



Rostrum abnormalities in the endangered Indian Ocean humpback dolphin (*Sousa plumbea*) in South Africa

Guilherme FRAINER,^{1,2} Simon ELWEN,^{2,3} Sasha DINES,^{2,3} Bridget JAMES,^{2,3} Els VERMEULEN,⁴ Gwenith PENRY,⁵ O. Alejandra VARGAS-FONSECA,^{5,6} Shanan ATKINS,⁷ Danielle CONRY⁸ and Tess GRIDLEY^{1,2,3}

¹Centre for Statistics in Ecology, Environment and Conservation, University of Cape Town, South Africa, ²Sea Search Research and Conservation, Cape Town, South Africa, ³Department of Botany and Zoology, Stellenbosch University, Stellenbosch, South Africa, ⁴Mammal Research Institute Whale Unit, Faculty of Natural and Agricultural Sciences, University of Pretoria, Pretoria, South Africa, ⁵Institute for Coastal and Marine Research, Nelson Mandela University, Gqeberha, South Africa, ⁶Department of Oceanography, Nelson Mandela University, Gqeberha, South Africa, ⁷Animal, Plant and Environmental Sciences, University of the Witwatersrand, Johannesburg, South Africa and ⁸Mammal Research Institute, Department of Zoology and Entomology, University of Pretoria, Pretoria, South Africa

Abstract

Morphological abnormalities in wild animals can be indicators of the underlying health of a population and may be determined through routine photographic surveys. Here, we assess unusual rostrum conditions in Indian Ocean humpback dolphins (*Sousa plumbea*) inhabiting South African coastal waters to understand the rate of prevalence of abnormal rostrums and formulate hypotheses on potential causes. Photographic data were collated from systematic boat surveys and opportunistic sightings, obtained between April 1998 and March 2021 in various regions along the South African coast. Overall, 31 unique individuals were found with abnormal rostrum conditions, varying from slight misalignments to severe wounds and/or aberrant morphologies. In most cases, injuries were likely caused by natural events during the animal's life history such as interactions with sharks and/or reef-associated hunting strategies. Mark–recapture data indicated that individuals had survived with these injuries for up to 10 years. This study reports the highest incidence of rostrum abnormalities in the species. As numbers reflect only those that have survived their injuries, they are considered a minimum estimate. A better understanding of the cause(s) of these injuries is important given the endangered status of this species.

Key words: endangered species, human impacts, injuries, mark-recapture, natural history

INTRODUCTION

Rostrum morphology plays a vital role in the feeding habits of toothed whales, both in terms of finding prey through echolocation (Song *et al.* 2016; Frainer *et al.* 2021) and for prey capture (Werth 2006). Consequently, wounds and/or congenital anomalies of this structure

Correspondence: Guilherme Frainer, Centre for Statistics in Ecology, Environment and Conservation, University of Cape Town, Private Bag X3, Rondebosch 7701, South Africa.
Email: gui.frainer@gmail.com

could directly affect the feeding strategies and abilities of individuals. Injuries in dolphins could be related to human activities such as vessel collisions (Elwen & Leeney 2010; Martinez & Stockin 2013) and entanglement in fishing gear (Wang *et al.* 2016, 2018), or from natural causes during their life history such as predation (Weisel *et al.* 2010), interspecific interactions (Patterson *et al.* 1998; Coscarella & Crespo 2009), and foraging adaptations (Caldwell & Brown 1964; Loch & Simões-Lopes 2013). Monitoring the prevalence of such injuries is critical, especially in endangered populations, to identify specific actions to mitigate possible human-caused injuries (Braulik *et al.* 2015).

Aberrant skeletal conditions are described for small dolphin populations (Robinson *et al.* 2020) such as the critically endangered vaquita (*Phocoena sinuata*), presenting congenital anomalies in the postcranial skeleton (Ortega-Ortiz *et al.* 2000), and the vulnerable Franciscana dolphin (*Pontoporia blainvillei*) exhibiting rostrum deviations (Denuncio *et al.* 2016). Congenital anomalies of head structures have been reported for other dolphin species as well (e.g. Dabin *et al.* 2004; Van Bresseem *et al.* 2006; Relvas *et al.* 2020; Post *et al.* 2021), but their causes are not typically known and many may be once-off occurrences. The high incidence of morphological abnormalities in isolated, small populations of mammals may reflect multifactorial causes such as genetic dysfunctions due to inbreeding and/or other environmental stressors linked to their life history (Hayden *et al.* 1994; Sokos *et al.* 2018; Robinson *et al.* 2020). In this way, morphological abnormalities could indicate cues for population vulnerability.

Indian Ocean humpback dolphins (*Sousa plumbea*, hereafter “humpback dolphins”) are coastal/estuarine dwelling dolphins distributed from the Bay of Bengal, northeastern Indian Ocean, to False Bay, South Africa (Jefferson & Rosenbaum 2014; Braulik *et al.* 2015). They exhibit a characteristic cartilaginous “hump” beneath their dorsal fin that is allusive of their common name, and a long narrow rostrum that often breaks the water first when surfacing. Humpback dolphins are the only resident marine mammal in South Africa listed as Endangered according to IUCN criteria, with approximately 500 individuals thought to occur in coastal waters of the country (Plön *et al.* 2015; Vermeulen *et al.* 2018). Their main threats include degradation of inshore habitats (Reeves & Leatherwood 1994), water pollution (Cockcroft 1999; Parra & Ross 2009), boat traffic (Karczmarski *et al.* 1998), shark-nets (Cockcroft 1990; Atkins *et al.* 2016), coastal development, overfishing, and climate change (Braulik *et al.* 2015; Bouveroux *et al.* 2018a). Individuals are known to move regularly between bays as

far as 200 km apart, with some movements up to 500 km detected along their south coast range (Vermeulen *et al.* 2018).

Here, photographic data sources were combined to describe and characterize rostrum abnormalities in humpback dolphins from South Africa. We provide insights into spatial patterns of occurrence and individual survival information, and discuss the potential causes for these abnormalities based on the available information from this endangered species.

MATERIALS AND METHODS

Photographs of humpback dolphins were collated and assessed for rostrum abnormalities. Data were available from 2 main sources: (1) a series of dedicated surveys that collected photo-identification (photo-ID) data on humpback dolphins between 2016 and 2021, and (2) opportunistic photographs of animals collected between 1998 and 2021. In the field, data collection mainly targeted dorsal fin images, with images of the head and body simultaneously collected for additional health assessments (e.g. scarring, skin disease). The unusual surfacing pattern of humpback dolphins, where the rostrum protrudes out of the water first on surfacing, aided our ability to observe rostral injuries for this species. Although all effort was made to match dorsal fin ID to the rostrum images, this was not always possible.

Dedicated surveys which encountered humpback dolphins were conducted in False Bay ($n = 7$ surveys), Gansbaai ($n = 2$), Struisbaai ($n = 7$), St. Sebastian Bay ($n = 6$), Mossel Bay ($n = 11$), and Richards Bay ($n = 4$), South Africa, between 2016 and 2021 (Fig. 1). Surveys were performed in shallow waters (less than 20 m depth) to optimize encounters with this coastal species (for further details, see James *et al.* 2015; Vermeulen *et al.* 2018). A Canon DSLR 6D camera with a 100–400 mm Canon lens was primarily used to photograph humpback dolphins and identify individuals by natural marks on their dorsal fins (Würsig & Würsig 1977) to ensure each individual was only counted once and could be re-identified over time. All available photographs from systematic surveys were searched for images of rostrums, and any abnormal looking rostrum was linked to a dorsal fin identity where possible (e.g. when a clear sequence of images was available). Photographs were cross-checked by 2 observers (authors: GF and SD) to verify the presence of abnormal rostrums and to reduce the subjectivity on assigning an abnormal condition. All photo-identified dolphins were compared to the South African National Catalogue (NC), which was built through a collaboration between several institutions

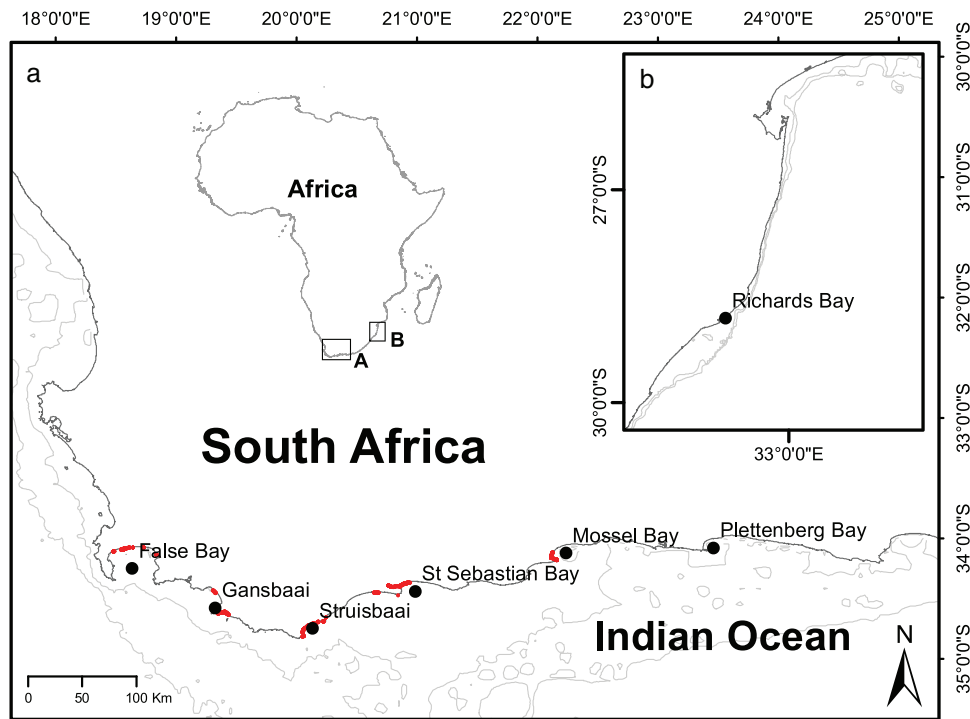


Figure 1 Dedicated surveys with confirmed Indian Ocean humpback dolphin encounters (red) were conducted in the southernmost portion of the species' distributional range in the Western Cape, Eastern Cape and KwaZulu-Natal, South Africa. Opportunistic sightings from Mossel Bay, Plettenberg Bay, and Richards Bay were included separately in the database.

(Vermeulen *et al.* 2018) within the *Sousa* Consortium–South Africa (hereafter, SouSA Consortium) (Plön *et al.* 2021). Known individuals were referred to using their NC number or given a new number if unmatched (e.g. ID01).

Opportunistic observations of humpback dolphins with abnormal rostrums were also collated following a request to all members of the SouSA Consortium and through other marine mammal communication channels (e.g. MARMAM list serve). This included individuals opportunistically photographed between 1998 and 2021, some in the same areas where dedicated surveys took place (St. Sebastian Bay, Mossel Bay, Plettenberg Bay, and Richards Bay), and some opportunistically photographed in areas not covered by systematic surveys. For opportunistic observations, only photographs of abnormal rostrums and their associated dorsal fins (when available) were used for analysis. Opportunistically obtained dorsal fins were matched with the NC where possible.

All images of individuals with abnormal conditions were assessed and each animal's condition was classified as: (1) injured rostrums, which varied from open wounds to healed ones (i.e. presenting callosities from scar tissue regeneration; Fig. 2a–f); and (2) aberrant rostrum con-

ditions, for those exhibiting deviations of the upper and/or lower jaw from the axis of the skull and without clear wound or regeneration scars (Fig. 2g–m). Rostral injuries and aberrant shapes were classified as either slight or severe.

RESULTS

In total, we characterized 31 distinct cases of rostrum abnormalities in humpback dolphins from coastal South Africa (Table 1). From the systematic surveys, 5530 photographs were processed, from which 121 individuals were identified by their dorsal fins thus representing around a quarter of the entire population. Of these, 13 individuals (11% of those assessed; Table 1) were unique cases presenting abnormal rostrums: 8 were injured, 4 were aberrant, and 1 individual was assigned as both conditions. Nine of the 13 animals with abnormal rostrum conditions were matched to the NC (Vermeulen *et al.* 2018). From the 6 locations where systematic surveys took place, the highest incidence of abnormalities were seen in St. Sebastian Bay ($n = 7$), with the remainder identified in Mossel Bay ($n = 5$). Opportunistic data




Figure 2 Abnormal rostrum conditions found in humpback dolphins from South African waters, including the period of the sighting history when available. (a) SA060, Mossel Bay (2011–2021), photo: R Logston/G Frainer; (b) SA087, Mossel Bay (2011–2021), photo: M Betts/T Gridley; (c) no ID, Richards Bay (2000–2002), photo: S Atkins; (d) ID01, Mossel Bay (2021), photo: G Frainer; (e) ID02, St. Sebastian Bay (2019), photo: G vdBerg; (f) no ID, Plettenberg Bay (2020), photo: D Conry; (g) SA043, Mossel Bay (2013–2021), photo: M Betts/T Gridley; (h) SA089, Mossel Bay (2014–2021), photo: M Betts/G Frainer; (i) SA051, St. Sebastian Bay (2016), photo: E Vermeulen; (j) no ID, Plettenberg Bay (2019), photo: D Conry; (l) ID03, St. Sebastian Bay (2019), photo: G vdBerg; (m) no ID, Plettenberg Bay (2018), photo: D Conry.

revealed an additional 18 individuals with abnormal rostral features, including 1 in Richards Bay (seen between 1998 and 2002), 1 in St. Sebastian Bay (seen in 2021), 4 in Mossel Bay (seen between 2013 and 2015), and 12 in Plettenberg Bay (seen between 2014 and 2019; Table 1). All opportunistic cases were considered unique individuals based on clear differences in the rostral abnormal features (Table 1, Fig. 2; Supporting Information). A short survey conducted through marine mammal communication channels did not result in any additional reports from South Africa, or reports of similar examples for other humpback dolphin (*Sousa* spp.) populations, or indeed other dolphin species worldwide.

A brief description of each abnormal rostrum is provided in Table 1, along with additional data on the individual. All abnormal rostrums observed were from adult individuals, and most (22 out of 31) were characterized as injured, rather than having an aberrant shape. Of these, 19 individuals had a clear broken rostrum, with bone tissue exposed in some cases (e.g. Fig. 2). Two individuals only had minor injuries to the rostrums (Supporting Information S16 and Fig. 2f) and one individual presented a large, straight horizontal notch at the base of the melon with an artifact attached to the left side of the rostrum which was identified as a fishing line (Supporting Information S18). Three individuals could be classified as females due to



Figure 2 *Continued*

the presence of an associated calf. The sex of all the other individuals remains undetermined.

Sighting histories generated from combining dedicated survey and opportunistic data showed that some individuals were identified across several years, with re-sights of 4 affected individuals spanning 10 years in Mossel Bay, demonstrating their high residency in the area. The greatest distance over which an affected individual could be recaptured (individual SA043) was approximately 130 km from Mossel Bay to St. Sebastian Bay between June 2011 and March 2021 (Table 1).

Although sporadic, the longitudinal nature of opportunistic data provided useful information on the sighting histories and survivorship of individuals, as well as temporal changes of the injury or aberrant shape for certain cases over time (Table 1). For example, individual SA043, presenting a clockwise-twisted rostrum, has been observed with this condition for at least 10 years with-

out considerable change (Fig. 2g). The aberrant rostrum shape of SA089 originated before 2014 and the individual has survived at least 7 years with this condition (Fig. 2h). Conversely, individual SA083 was observed to change overtime, acquiring a wound at the tip of the upper jaw between 2013 (Mossel Bay) and 2019 (Plettenberg Bay; Supporting Information S15). For SA060 (Fig. 2a) and SA087 (Fig. 2b), we documented deterioration in the injury over time, and in both cases, a mutilation of part of the rostrum was detected.

The most detailed case study is that of a female dolphin first recorded in Richards Bay. The animal was first sighted in 1998 with a calf and was identified on 29 occasions without an injury. Her wound was first observed in October 1999 when her second known calf was 4–6 months old. The animal had a broken upper jaw with the tip sustained only by soft tissues just in front of the melon so that the upper jaw was at a right angle (Fig. 2c).

Table 1 Individual descriptions for each case of abnormal rostrum conditions recorded in this study, including the individual's sighting history and the source of the data

Location	ID	Time-frame	Type of abnormality	Condition	Description	Data source
FB	SA007	2016	I	SL	The left side of the upper jaw tip seems to present a healed wound (Supporting Information S1).	S
SSB	SA041	2016	A/I	SL	The upper and lower jaw seems to be twisted clockwise, thus presenting axial misalignment of the rostrum bones. The tip of the mandible seems to be broken (Supporting Information S2).	S
SSB	SA046	2016	I	SV	Anterior half of both upper and lower jaw removed, exhibiting surrounding scars from regeneration (Supporting Information S3).	S
SSB	SA051	2016	A	SV	This individual presented the highest degree of an aberrant condition in this study, as the upper jaw is twisted to the right side and aligned anteroventrally to its base, while the lower jaw seems broken at its tip and is turned dorsally (Fig. 2i).	S
SSB/SB	SA052	2017	I	SV	The anterior half of both upper and lower jaws is removed, and it exhibits regeneration scars surrounding its tip (Supporting Information S4).	S
SSB	ID02	2019	I	SV	The anterior half of both upper and lower jaws is removed (Fig. 2e).	S
SSB	ID03	2019	A	SV	The upper jaw is slightly skewed to the left side and the mandible exhibits an unusual concave shape and its' tip is turned dorsally (Fig. 2l).	S
SSB/SB	ID04	2017	I	SV	The tip of the upper jaw seems to be broken, being sustained by soft tissues at the left side (Supporting Information S5).	S
SSB/MB	SA043 (♀)	2011–2021	A	SL	The upper and lower jaws seem to be twisted clockwise, thus presenting axial misalignment of the rostrum bones. The animal exhibited the condition from 2013 onwards (Fig. 2g).	O/S
SSB	no ID	2021	I	SL	The tip of the upper jaw presents a healed wound, with callosities of skin regeneration (Supporting Information S6).	O
MB	SA060	2011–2021	I	SV	The anterior half of both upper and lower jaw is removed, exhibiting regeneration scars. Photographs from 2011 showed that the animal still had the tip of the lower jaw suspended by soft tissues (Fig. 2a).	O/S
MB	SA063	2011	I	SL	The tip of the mandible seems to be broken and skewed to the left (Supporting Information S7).	O
MB	SA070	2011	I	SV	The tip of the mandible was removed, showing a fresh scar and bone tissues as well (Supporting Information S8).	O

(Continued)

Table 1 (Continued)

Location	ID	Time-frame	Type of abnormality	Condition	Description	Data source
MB	SA074	2011–2013	I	SV	The right hand-side portion of the tip of the rostrum presents a wound with apparently bone exposure (Supporting Information S9).	O
MB	SA083	2013	A	SL	The upper and lower jaw seems to be twisted counter-clockwise, thus presenting axial misalignment of the rostrum bones (Supporting Information S15).	O
MB	SA087	2011–2021	I	SV	This individual was first sighted in 2011 presenting an apparent injury of the tip of the upper jaw, with regeneration scars on the top of it. This same condition was also observed in 2013 and 2014. During the dedicated surveys in Mossel Bay, 2021, the same individual exhibited half of its lower jaw removed and bone tissue was exposed. Regeneration scars were observed surrounding the tip of the remaining rostrum (Fig. 2b).	O/S
MB	SA089 (♀)	2014–2021	A	SV	This individual presented an aberrant, unique condition where the upper jaw was deviated 90° to the left from the middle portion of the rostrum. The condition of this animal was first observed in early 2014 (Fig. 2h).	O/S
MB	ID01	2021	I	SV	The tip of the upper jaw was removed, exposing bone tissue (Fig. 2d).	S
PB	No ID	2015	I	SL	Both upper and lower jaw tips presented a healed wound, with both tips removed. The lower jaw exhibits a protuberance at its tip on the left side, but no bone is exposure (Supporting Information S10).	O
PB	No ID	2015	A	SL	Mandible slightly skewed to the right (Supporting Information S11).	O
PB	No ID	2014	A	SL	Rostrum twisted clockwise, as the upper jaw is skewed to the right and the mandible to the left (Supporting Information S12).	O
PB	No ID	2014	I	SV	The tip of the upper and lower jaws seems to be slightly skewed to the left (Supporting Information S13).	O
PB	No ID	2018	I	SL	Healed wound at the tip of the mandible with callosities from scar regeneration on the left-hand side (Supporting Information S14).	O
PB/MB	SA083	2013–2019	I	SV	Tip of the upper jaw broken, with a small portion of soft tissue turned dorsally. This animal was sighted in Mossel Bay in 2013 without any rostrum wounds (Supporting Information S15).	O
PB	No ID	2018–2019	A	SL	Tip of the mandible slightly skewed to the left (Fig. 2m).	O

(Continued)

Table 1 (Continued)

Location	ID	Time-frame	Type of abnormality	Condition	Description	Data source
PB	No ID	2019	I	SL	Small wound at the tip of the mandible (Supporting Information S16).	O
PB	No ID	2019	I	SV	Tip of both upper and lower jaw broken (Supporting Information S17).	O
PB	No ID	2019	I	SL	Individual presenting a horizontal notch at the base of the melon (Supporting Information S18).	O
PB	No ID	2019	A	SL	Rostrum twisted counterclockwise, i.e., the upper jaw skewed to the left and the mandible to the right (Fig. 2j).	O
PB	no ID	2020	I	SL	Tip of the mandible slightly injured, with some tooth marks from intraspecific interactions (Fig. 2f).	O
RB	No ID (♀)	1998–2002	I	SV	Anterior half of the upper jaw is apparently broken but with the tip being suspended by soft tissues just in front of the melon (Fig. 2c).	O

FB, False Bay; SSB, St Sebastian Bay; SB, Struis Bay; MB, Mossel Bay; PB, Plettenberg Bay; RB, Richards Bay; I, injured; A, aberrant condition; SL, slight; SV, severe; S, dedicated survey; O, opportunistic data.

The injury was only observed, not photographed, until 2000 when rostrum photographs were first taken. The individual was resighted with no further changes to the rostrum until November 2002 when the female and her third-known calf were both fatally entangled in the Richards Bay shark nets. The skull of this individual is available in the Port Elizabeth Museum (PEM3028), Gqeberha, South Africa.

DISCUSSION

Humpback dolphins in South Africa are locally and globally endangered with numbers decreasing and multiple threats to the species (Braulik *et al.* 2015). One case of rostrum abnormality presented herein was clearly related to fishing line entanglement (Supporting Information S18), and entanglement of this nature might represent an additional threat to this population (Machernis *et al.* 2021). No other case reported here showed injuries likely resulting from human activities such as boat strikes or fishing activities. In our study, all observed abnormal rostrum conditions were in adults, further supporting the likelihood that these result from events related to their life history rather than genetic dysfunctions. Aberrant conditions linked to low genetic diversity in some small dolphin populations seem to be more prevalent in dependent calves (e.g., 7.4% of calves in the northeastern Scottish population of *T. truncatus*,

see Robinson *et al.* 2020) which decrease the chances of individual survival (Valsecchi *et al.* 2004). This might not be the case for South African humpback dolphins, although this population does exhibit low mitochondrial genetic diversity which represents another factor in its vulnerability (Lampert *et al.* 2021).

The unusual rostrum morphology found in humpback dolphins could represent a natural but inconvenient situation for the southernmost portion of the South African population. The morphological abnormalities characterized here seem to be specific to this species, as no similar cases could be found in this or other species in the *Sousa* genus, and only one similar case could be found in coastal bottlenose dolphins (Gibson *et al.* 2020). A few cases of morphological abnormalities potentially linked to congenital disorders are reported in humpback dolphin species (*Sousa chinensis* and *Sousa teuszii*), but these were all related to vertebral anomalies of the affected individuals (Weir & Wang 2016).

Although we were unable to determine the exact cause of the abnormal rostrum conditions presented here, it is suspected that multiple factors may be involved. Injuries to rostrums may result from a number of potential causes that are discussed in more detail below:

(1) Skull morphology and development

Species with longer rostrums might be more susceptible to injuries compared to those with shorter, more

robust beaks (Gerholdt 2006). We considered aberrant conditions for those cases in which injuries were not evident (e.g. Fig. 2g–m) to avoid overlooking any potential occurrences of congenital anomalies in this population. Our results showed a relatively similar incidence of abnormal rostrum conditions to that of Franciscana dolphins, which have similarly long rostrums, as 10% of the specimens assessed by Denuncio *et al.* (2016) presented beak deviations. These species present distinct patterns of rostrum morphology, but they both depend on postnatal ontogeny for its maturation (Frainer *et al.* 2015, 2021). Humpback dolphins present a peculiar anteriorization (i.e. increased timing of formation) of the tip of the mandible during the postnatal ontogeny compared to other delphinids (Supporting Information S13 from Frainer *et al.* 2021), thus potentially addressing the shape plasticity found at the tip of the rostrum in some individuals. As the learning process to achieve the best performance of certain stereotyped behaviors may be extensive (Galef & Laland 2005), injuries may be common at young ages and their effects long lasting. In this way, it is plausible that the aberrant conditions reported here could be healed injuries with additional shape changes because the postnatal development is important for the formation of the singular long-rostrum, delphinid-like head bauplan found in this species (Frainer *et al.* 2021).

(2) Hunting strategies

Experienced adults might perform complex stereotyped behaviors for hunting (Peddemors & Thompson 1994). Humpback dolphins are rarely seen feeding in South African waters due to their preference for demersal prey and affinity for murky estuarine habitats (Barros & Cockcroft 1991). Thus, most of the knowledge on feeding strategies is limited to surface behaviors (Karczmarski *et al.* 1997), stomach content analysis of dolphins bycaught along the east coast (Plön *et al.* 2015), and observations from other study areas (Lin *et al.* 2021).

Humpback dolphins are known for being specialist reef hunters (Plön *et al.* 2015; Lin *et al.* 2021), which rely on skills developed to hunt on reefs where larger prey are found (Barros & Cockcroft 1991). Saayman and Tayler (1979) described an unusual behavior for a captive humpback dolphin where the animal “...spent much time poised vertically, head downwards, above the reefs in the tank (at the Port Elizabeth Museum, South Africa) and investigated crevices and crannies with their long rostrums, snapping with a sideways motion of the head at any rock-dwelling fish which emerged”. Similarly, bottlenose dolphins from the Bahamas present this so-called “crater-feeding,” where the bottom is inspected and dolphins dig

the sand with their heads looking for fishes (Rossbach & Herzing 1997). In this way, reef-associated hunting strategies could also result in rostral injuries both by collision with sharp reefs or potentially getting their rostrum stuck in crevices in reefs (Saayman & Tayler 1979).

(3) Predator defense

Adult humpback dolphins are often seen with deep scars from interactions with sharks (Wcisel *et al.* 2010), which may aid individual identification. Interestingly, humpback dolphins caught in shark nets exhibited a higher incidence of shark bites than Indo-Pacific bottlenose dolphins (*Tursiops aduncus*) (hereafter, bottlenose dolphins) implying that humpback dolphins experience relatively high predation pressure from sharks (Cockcroft 1991). Since few individuals shorter than 200 cm total length presented shark scars, Cockcroft (1991) proposed that females might attempt to protect their calves during shark attacks. Coincidentally, all abnormal rostrums described here were seen in adult individuals and the only 3 animals with sex information were females due to calf presence. In this way, it is plausible that interspecific interactions with predators could result in skin and/or rostral injuries such as those demonstrated here. Alternately, smaller animals suffering from these injuries (especially if related to defense against sharks) may not have survived.

(4) Intra-specific interactions

Violent intra-specific interactions are known to cause injuries in bottlenose dolphins (Erin *et al.* 2005). Likewise, the Indo-Pacific humpback dolphin (*S. chinensis*) has been observed attempting infanticide and succeeding (Zheng *et al.* 2016). This included behaviors such as ramming “*hitting the target individual with the rostrum or torso, usually after sudden acceleration, frequently performed by several perpetrators simultaneously or in succession and repeated several times*” and body-slamming. The authors also noticed accompanying adults, presumably females, defending their calves from harassment. These actions are sufficient to fracture ribs and kill calves (Zheng *et al.* 2016) and could also result in injuries on both aggressor and, potentially, females attempting to protect their calves.

(5) Inter-specific interactions

There is much to suggest that bottlenose dolphins are violent toward other species of dolphins and that they inflict trauma that is characterized by multiple skeletal fractures, though the species involved are generally smaller than humpback dolphins (Ross & Wilson 1996; Wedekin *et al.* 2004; Coscarella & Crespo 2009). The

south coast population of bottlenose dolphins in South Africa are almost completely sympatric with humpback dolphins and highly abundant (Reisinger & Karczmarski 2010; Caputo *et al.* 2021), including having among the largest group sizes for the species seen anywhere globally (Bouveroux *et al.* 2018b). At least, one aggressive interaction between humpback dolphins and bottlenose dolphins has been recorded in the country (Saayman & Tayler 1979). Additionally, humpback dolphins in Algoa Bay and Zanzibar tend to avoid bottlenose dolphins; this was proposed as an indication of costly interactions (Stensland *et al.* 2003; Koper & Plön 2016). Inter-specific aggressive behaviors have also been noted in other species of *Sousa*. For example, in interactions between Australian humpback dolphins (*Sousa sahulensis*) and snubfin dolphins (*Orcaella heinsohni*), the humpback dolphins were frequently aggressive toward the smaller snubfins; and snubfins resisted the interactions, sometimes using their “rostrum, head or side of the body against the humpback dolphins” (Parra 2006). Thus, it is possible that the rostral injuries reported here could result from negative interactions with other dolphins such as bottlenose dolphins.

(6) Contaminants

Cetaceans are highly threatened by accumulation of contaminants when residing near industrialized areas in South Africa (Aznar-Aleman *et al.* 2019). Nationally, humpback dolphins off KwaZulu-Natal, South Africa, have been recorded with the highest levels of organochlorines of any marine mammal off South Africa (Cockcroft 1999) and DDT concentrations in humpback dolphins from South Africa are among the highest levels reported in delphinids globally (Gui *et al.* 2016). The high prevalence of contaminants in humpback dolphins in South Africa could have physiological effects. For example, elevated exposure to contaminants such as biphenyl ethers (PCBs) and polybrominated diphenyl ethers (PBDEs) has been associated with decreased bone mass density in polar bear skulls (Sonne *et al.* 2004). In humpback dolphins, these toxins are also transferred from mothers to their calves through lactation (Cockcroft *et al.* 1989). In this way, injuries on the rostrum could be exacerbated due to low bone density caused by contaminants thus resulting in the severe conditions observed.

This is not the first report of abnormalities in humpback dolphins. Saayman and Tayler (1979) reported 2 humpback dolphins showing “misaligned” mandibles, one in captivity and another in the wild, in Plettenberg Bay, Western Cape, South Africa. The authors often spotted the dolphins from land but without photographic records, so no detailed descriptions are available of those

conditions. Nonetheless, it shows a historical occurrence of injured/aberrant rostrums for humpback dolphins in the region, over 50 years ago, when anthropogenic impacts along the coastline were less.

Humpback dolphins (*Sousa* spp.) seem to be resilient to extreme rostrum conditions following injuries (Wang *et al.* 2016). This fact highlights the ability of these animals to adapt and adjust their feeding strategies (Werth 2006) and maintain their ability to produce and perceive sounds while exhibiting injuries in a key structure of their biosonar apparatus (Frainer *et al.* 2019, 2021). In this study, female SA089 (Fig. 2g) survived at least 7 years with her abnormal rostrum. The 3 individuals sighted within 10 years in Mossel Bay represent the longest known period recorded of individuals with injured feeding apparatus for this species. The injuries of 2 of them (SA060 and SA087) have worsened over time, suggesting the continuous potential for new injuries. The individual sighted in Richards Bay in the late 90s showed extensive injury to part of her rostrum in front of the sound production apparatus, which likely affected its sound transmission mechanisms and thus the animal’s ability to orientate and hunt. However, this female not only survived but also reproduced, as she successfully raised a calf (which was 4–6 months old when its mother’s injury occurred) and gave birth to another calf in 2002—nearly 3 years after the injury—before being caught with this calf in a shark net (Atkins *et al.* 2013).

The damage, caused through either injury or genetic malfunction possibly leading to pre-disposition for breakages, may indicate that these dolphins are at a greater threat than previously recognized. Open wounds associated with the initial stages of the rostral injuries reported here may further increase their vulnerability to contracting infectious diseases (Kompanje 1995), thus, potentially becoming an additional threat to this dolphin population. The high incidence of abnormal rostrum conditions in humpback dolphins highlights the importance of assessing the impacts of this phenomenon on population health, as well as the necessity of mitigating the current threats on this endangered species.

ACKNOWLEDGMENTS

This research was possible due to the collaboration of the SouSA consortium members that involve multiple institutions. This study was supported by a National Research Foundation grant awarded to T.G. (Grant number: 116047), and including G.F.’s postdoctoral fellowship and S.D.’s PhD scholarship. O.A.V.-F. was funded by a Nelson Mandela University Postgraduate

Research Scholarship (2015–2018) and supported by the MARISCO project (FAIN: 2019902/KK2153), which is funded by the Belmont Forum (2021/2022). Research was conducted under a series of research permits issued by the Department of Environment Forestry and Fisheries (and its predecessors) to S.E. (RES 2015/94 to 2021/26) and O.A.V.-F. (RES 2013/67 AND RES 2015/79). This study was carried out and under ethics clearance from the University of Pretoria Animal Use and Care Committee permit (EC074-15), the Stellenbosch University AUCC (ACU-2021-13330), and by Nelson Mandela University animal ethics clearance (A13-SCI-ZOO-001). We are grateful to Orca Foundation for field work assistance, as well as for the Rufford Foundation, the Society for Marine Mammalogy, and the German Society for Dolphin Conservation (Gesellschaft zur Rettung der Delphine) for financial support in Plettenberg Bay (2013–2015).

REFERENCES

- Atkins S, Cantor M, Pillay N, Cliff G, Keith M, Parra GJ (2016). Net loss of endangered humpback dolphins: Integrating residency, site fidelity, and bycatch in shark nets. *Marine Ecology Progress Series* **555**, 249–60.
- Atkins S, Cliff G, Pillay N (2013). Humpback dolphin bycatch in the shark nets in KwaZulu-Natal, South Africa. *Biological Conservation* **159**, 442–9.
- Aznar-Alemany Ò, Sala B, Plön S, Bouwman H, Barceló D, Eljarrat E (2019). Halogenated and organophosphorus flame retardants in cetaceans from the southwestern Indian Ocean. *Chemosphere* **226**, 791–9.
- Barros NB, Cockcroft VG (1991). Prey of humpback dolphins (*Sousa plumbea*) stranded in eastern Cape Province, South Africa. *Aquatic Mammals* **17**, 134–6.
- Bouveroux T, Melly B, McGregor G, Plön S (2018a). Another dolphin in peril? Photo-identification, occurrence, and distribution of the endangered Indian Ocean humpback dolphin (*Sousa plumbea*) in Algoa Bay. *Aquatic Conservation: Marine and Freshwater Ecosystems* **28**, 723–32.
- Bouveroux TN, Caputo M, Froneman PW, Plön S (2018b). Largest reported groups for the Indo-Pacific bottlenose dolphin (*Tursiops aduncus*) found in Algoa Bay, South Africa: Trends and potential drivers. *Marine Mammal Science* **34**, 645–65.
- Braulik GT, Findlay K, Cerchio S, Baldwin R (2015). Chapter five—Assessment of the conservation status of the Indian Ocean humpback dolphin (*Sousa plumbea*) using the IUCN Red List criteria. In: Jefferson TA, Curry BE, eds. *Advances in Marine Biology*. Academic Press, Cambridge, MA, pp. 119–41.
- Caldwell DK, Brown DH (1964). Tooth wear as a correlate of described feeding behavior by the Killer Whale, with notes on a captive specimen. *Bulletin Southern California Academy of Sciences* **63**, 128–40.
- Caputo M, Bouveroux T, Froneman PW, Shaanika T, Plön S (2021). Occurrence of Indo-Pacific bottlenose dolphins (*Tursiops aduncus*) off the Wild Coast of South Africa using photographic identification. *Marine Mammal Science* **37**, 220–34.
- Cockcroft V (1991). Incidence of shark bites on Indian Ocean hump-backed dolphins (*Sousa plumbea*) off Natal, South Africa. In: Leatherwood S, Donovan G, eds. *Cetaceans and Cetacean Research in the Indian Ocean Sanctuary*. Marine Mammal Technical Report Number 5, United Nations Environment Programme, Nairobi, pp. 277–82.
- Cockcroft V (1999). Organochlorine levels in cetaceans from South Africa: a review. *Journal of Cetacean Research and Management* (Special Issue 1), 169–76. <https://doi.org/10.47536/jcrm.v1i1.262>
- Cockcroft VG (1990). Dolphin catches in the Natal shark nets, 1980 to 1988. *African Journal of Wildlife Research* **20**, 44–51.
- Cockcroft VG, De Kock AC, Lord DA, Ross GJB (1989). Organochlorines in bottlenose dolphins *Tursiops truncatus* from the east coast of South Africa. *South African Journal of Marine Science* **8**, 207–17.
- Coscarella MA, Crespo EA (2009). Feeding aggregation and aggressive interaction between bottlenose (*Tursiops truncatus*) and Commerson's dolphins (*Cephalorhynchus commersonii*) in Patagonia, Argentina. *Journal of Ethology* **28**, 183.
- Dabin W, Cesarini C, Clemenceau I *et al.* (2004). Double-faced monster in the bottlenosed dolphin (*Tursiops truncatus*) found in the Mediterranean Sea. *Veterinary Record: Journal of the British Veterinary Association* **154**, 306–8.
- Denuncio P, Panebianco MV, Del Castillo D, Rodríguez D, Cappozzo HL, Bastida R (2016). Beak deviations in the skull of Franciscana dolphins *Pontoporia blainvillei* from Argentina. *Diseases of Aquatic Organisms* **120**, 1–7.
- Elwen SH, Leeney RH (2010). Injury and subsequent healing of a propeller strike injury to a Heaviside's dolphin (*Cephalorhynchus heavisidii*). *Aquatic Mammals* **36**, 382.

- Erin MS, Mann J, Jana JW-C, Brooke LS, Connor RC (2005). Aggression in bottlenose dolphins: Evidence for sexual coercion, male-male competition, and female tolerance through analysis of tooth-rake marks and behaviour. *Behaviour* **142**, 21–44.
- Frainer G, Huggenberger S, Moreno IB (2015). Postnatal development of franciscana's (*Pontoporia blainvillei*) biosonar relevant structures with potential implications for function, life history, and bycatch. *Marine Mammal Science* **31**, 1193–1212.
- Frainer G, Huggenberger S, Moreno IB, Plön S, Galatius A (2021). Head adaptation for sound production and feeding strategy in dolphins (Odontoceti: Delphinida). *Journal of Anatomy* **238**, 1070–81.
- Frainer G, Plön S, Serpa NB, Moreno IB, Huggenberger S (2019). Sound generating structures of the humpback dolphin *Sousa plumbea* (Cuvier, 1829) and the directionality in dolphin sounds. *The Anatomical Record* **302**, 849–60.
- Galef BG, Laland KN (2005). Social learning in animals: Empirical studies and theoretical models. *BioScience* **55**, 489–99.
- Gerholdt JM (2006). Abnormalities and pathologies in the snout of the La Plata Dolphin (*Pontoporia blainvillei*). *The Ecphora* **22**, 1–5.
- Gibson CE, Williams D, Dunlop R, Beck S (2020). Using social media as a cost-effective resource in the photo-identification of a coastal bottlenose dolphin community. *Aquatic Conservation: Marine and Freshwater Ecosystems* **30**, 1702–10.
- Gui D, Karczmarski L, Yu R-Q *et al.* (2016). Profiling and spatial variation analysis of persistent organic pollutants in South African Delphinids. *Environmental Science & Technology* **50**, 4008–17.
- Hayden TJ, Lynch JM, O'Corry-Crowe G (1994). Antler growth and morphology in a feral sika deer (*Cervus nippon*) population in Killarney, Ireland. *Journal of Zoology* **232**, 21–35.
- James BS, Bester MN, Penry GS, Gennari E, Elwen SH (2015). Abundance and degree of residency of humpback dolphins *Sousa plumbea* in Mossel Bay, South Africa. *African Journal of Marine Science* **37**, 383–94.
- Jefferson TA, Rosenbaum HC (2014). Taxonomic revision of the humpback dolphins (*Sousa* spp.), and description of a new species from Australia. *Marine Mammal Science* **30**, 1494–541.
- Karczmarski L, Cockcroft VG, McLachlan A, Winter PED (1998). Recommendations for the conservation and management of humpback dolphins *Sousa chinensis* in the Algoa Bay region, South Africa. *Koedoe - African Protected Area Conservation and Science* **41**, 9.
- Karczmarski L, Thornton M, Cockcroft VG (1997). Description of selected behaviours of humpback dolphins. *Aquatic Mammals* **233**, 127–33.
- Kompanje EJO (1995). Differences between spondyloosteomyelitis and spondylosis deformans in small odontocetes based on museum material. *Aquatic Mammals* **21**, 199–204.
- Koper RP, Plön S (2016). Interspecific interactions between cetacean species in Algoa Bay, South Africa. *Aquatic Mammals* **42**, 454.
- Lampert S, Ingle RA, Jackson JA, Gopal K, Plön S (2021). Low mitochondrial genetic diversity in the Indian Ocean humpback dolphin *Sousa plumbea* in South African waters. *Endangered Species Research* **46**, 91–103.
- Lin W, Karczmarski L, Zhou R *et al.* (2021). Prey decline leads to diet shift in the largest population of Indo-Pacific humpback dolphins? *Integrative Zoology* **16**, 548–74.
- Loch C, Simões-Lopes PC (2013). Dental wear in dolphins (Cetacea: Delphinidae) from southern Brazil. *Archives of Oral Biology* **58**, 134–41.
- Machernis AF, Stack SH, Olson GL, Sullivan FA, Currie JJ (2021). External scarring as an indicator of fisheries interactions with bottlenose (*Tursiops truncatus*) and pantropical spotted (*Stenella attenuata*) dolphins in Maui Nui, Hawai'i. *Aquatic Mammals* **47**, 482–98.
- Martinez E, Stockin KA (2013). Blunt trauma observed in a common dolphin *delphinus* sp. likely caused by a vessel collision in the Hauraki Gulf, New Zealand. *Pacific Conservation Biology* **19**, 19–27.
- Ortega-Ortiz JG, Villa-Ramírez B, Gersenowies JR (2000). Polydactyly and other features of the manus of the vaquita, *Phocoena sinus*. *Marine Mammal Science* **16**, 277–86.
- Parra GJ (2006). Resource partitioning in sympatric delphinids: space use and habitat preferences of Australian snubfin and Indo-Pacific humpback dolphins. *Journal of Animal Ecology* **75**, 862–74.
- Parra GJ, Ross G (2009). The Indo-Pacific humpback dolphin, *Sousa chinensis*. In: Perrin WF, Wursig B, Thewissen JGM, eds. *Encyclopedia of Marine Mammals*. American Press, London, pp. 576–81.
- Patterson IAP, Reid RJ, Wilson B, Grellier K, Ross HM, Thompson PM (1998). Evidence for infanticide in bottlenose dolphins: an explanation for violent

- interactions with harbour porpoises? *Proceedings of the Royal Society of London B: Biological Sciences* **265**, 1167–70.
- Peddemors V, Thompson G (1994). Beaching behaviour during shallow water feeding by humpback. *Aquatic Mammals* **20**, 65–7.
- Plön S, Atkins S, Cockcroft V *et al.* (2021). Science alone won't do it! South Africa's endangered humpback dolphins *Sousa plumbea* Face complex conservation challenges. *Frontiers in Marine Science* **8**, 642226.
- Plön S, Cockcroft VG, Froneman WP (2015). The natural history and conservation of Indian Ocean humpback dolphins (*Sousa plumbea*) in South African waters. In: Jefferson TA, Curry BE, eds. *Advances in Marine Biology*. Academic Press, Oxford, pp. 143–62.
- Post J, Samuelson MM, Moore DP, Solangi M (2021). Brachygnathia superior observed in a juvenile common bottlenose dolphin (*Tursiops truncatus*). *Aquatic Mammals* **47**, 371–5.
- Reeves RR, Leatherwood S (1994). *Dolphins, Porpoises, and Whales: 1994–1998 Action Plan for the Conservation of Cetaceans*. IUCN, Gland, Switzerland.
- Reisinger RR, Karczmarski L (2010). Population size estimate of Indo-Pacific bottlenose dolphins in the Algoa Bay region, South Africa. *Marine Mammal Science* **26**, 86–97.
- Relvas CI, Moore M, Milmann L (2020). Blowhole anomaly in pantropical spotted dolphin (Delphinidae: *Stenella attenuata*). *Marine Mammal Science* **36**, 1334–8.
- Robinson KP, Haskins GN, Eisfeld-Pierantonio SM, Sidiropoulos T, Bamford CCG (2020). Presenting vertebral deformities in bottlenose dolphin *Tursiops truncatus* calves from a protected population in north-east Scotland. *Diseases of Aquatic Organisms* **140**, 103–8.
- Ross HM, Wilson B (1996). Violent interactions between bottlenose dolphins and harbour porpoises. *Proceedings of the Royal Society of London B: Biological Sciences* **263**, 283–6.
- Rossbach KA, Herzing DL (1997). Underwater observations of benthic-feeding bottlenose dolphins (*Tursiops truncatus*) near Grand Bahama Island, Bahamas. *Marine Mammal Science* **13**, 498–504.
- Saayman GS, Tayler CK (1979). The socioecology of humpback dolphins (*Sousa* sp.). In: Winn HE, Olla BL, eds. *Behavior of Marine Animals: Current Perspectives in Research*. Springer US, Boston, MA, pp. 165–226.
- Sokos C, Kollaris N, Papaspyropoulos KG, Poirazidis K, Birtsas P (2018). Frequency of abnormalities in wildlife species: is there a relation with their ecology? *Zoology and Ecology* **28**, 389–94.
- Song Z, Zhang Y, Wei C, Wang X (2016). Inducing rostrum interfacial waves by fluid-solid coupling in a Chinese river dolphin (*Lipotes vexillifer*). *Physical Review E* **93**, 012411.
- Sonne C, Dietz R, Born Erik W *et al.* (2004). Is bone mineral composition disrupted by organochlorines in East Greenland polar bears (*Ursus maritimus*)? *Environmental Health Perspectives* **112**, 1711–6.
- Stensland EVA, Angerbjörn A, Berggren PER (2003). Mixed species groups in mammals. *Mammal Review* **33**, 205–23.
- Valsecchi E, Amos W, Raga JA, Podestà M, Sherwin W (2004). The effects of inbreeding on mortality during a morbillivirus outbreak in the Mediterranean striped dolphin (*Stenella coeruleoalba*). *Animal Conservation* **7**, 139–46.
- Van Bresse M-F, Koen Van W, David M *et al.* (2006). Diseases, lesions and malformations in the long-beaked common dolphin *Delphinus capensis* from the Southeast Pacific. *Diseases of Aquatic Organisms* **68**, 149–65.
- Vermeulen E, Bouveroux T, Plön S *et al.* (2018). Indian Ocean humpback dolphin (*Sousa plumbea*) movement patterns along the South African coast. *Aquatic Conservation: Marine and Freshwater Ecosystems* **28**, 231–40.
- Wang X, Jutapruet S, Huang S-L, Turvey S, Wu F, Zhu Q (2018). External injuries of Indo-Pacific humpback dolphins (*Sousa chinensis*) in Xiamen, China, and its adjacent waters as an indicator of potential fishery interactions. *Aquatic Mammals* **44**, 285–92.
- Wang X, Wu F, Ding X, Zhu Q (2016). Record of an Indo-Pacific humpback dolphin (*Sousa chinensis*) without its upper rostrum in Xiamen Bay, Fujian Province, China. *New Zealand Journal of Zoology* **43**, 299–306.
- Weisel M, Chivell W, Gottfried MD (2010). A potential predation attempt by a great white shark on an Indo-Pacific humpback dolphin. *South African Journal of Wildlife Research* **40**, 184–7.
- Wedekin LL, Daura-Jorge FG, Simões-Lopes PC (2004). An aggressive interaction between bottlenose dolphins (*Tursiops truncatus*) and estuarine dolphins (*Sotalia guianensis*) in southern Brazil. *Aquatic Mammals* **30**, 391–7.

- Weir CR, Wang JY (2016). Vertebral column anomalies in Indo-Pacific and Atlantic humpback dolphins *Sousa* spp. *Diseases of Aquatic Organisms* **120**, 179–87.
- Werth AJ (2006). Mandibular and dental variation and the evolution of suction feeding in Odontoceti. *Journal of Mammalogy* **87**, 579–88.
- Würsig B, Würsig M (1977). The photographic determination of group size, composition, and stability of coastal porpoises (*Tursiops truncatus*). *Science* **198**, 755–6.
- Zheng R, Karczmarski L, Lin W, Chan SCY, Chang W-L, Wu Y (2016). Infanticide in the Indo-Pacific

humpback dolphin (*Sousa chinensis*). *Journal of Ethology* **34**, 299–307.

SUPPLEMENTARY MATERIALS

Additional supporting information may be found online in the Supporting Information section at the end of the article.

Supporting Information Appendix 1. Photographs of the abnormal rostrum conditions characterized in this study with corresponding ID number (if available), locality, time, and credits.

Cite this article as:

Frainer G, Elwen S, Dines S *et al.* (2022). Rostrum abnormalities in the endangered Indian Ocean humpback dolphin (*Sousa plumbea*) in South Africa. *Integrative Zoology* **00**, 1–14. <https://doi.org/10.1111/1749-4877.12685>